UNIVERSITE FRANCOIS-RABELAIS de TOURS
École Doctorale : Santé, Sciences, Technologies
Année Universitaire : 2008-2009

THESE POUR L'OBTENTION DU GRADE DE DOCTEUR DE L'UNIVERSITE DE TOURS

Discipline : Sciences de la vie
Présentée et soutenue publiquement
Par :

Patrick FRANÇOIS

Le 26 Octobre 2009

Étude anatomique macroscopique et ultrastructurale de la dure-mère au niveau de la région périsellaire

Directeur de Thèse :
Stéphane VELUT, professeur à l'Université François Rabelais
Directeur du Laboratoire d'Anatomie de la Faculté de Médecine

JURY

Président

- **Monsieur Michel JAN**

Professeur de Neurochirurgie, Université François Rabelais de Tours, Chirurgien des hôpitaux, Neurochirurgien, CHRU de Tours

Rapporteurs

- **Monsieur Gilles BRASSIER**

Professeur de Neurochirurgie, Université de Rennes, Chirurgien des hôpitaux, Neurochirurgien, CHU de Rennes

- **Monsieur Henri Dominique FOURNIER**

Professeur d'Anatomie, Université d'Angers, Chirurgien des hôpitaux, Neurochirurgien, CHU d'Angers

Examinateurs

- **Monsieur Stéphane VELUT**

Professeur d'Anatomie, Université François Rabelais de Tours, Chirurgien des hôpitaux, Neurochirurgien, CHRU de Tours

- **Monsieur Benoît BATAILLE**

Professeur de Neurochirurgie, Université de Poitiers, Chirurgien des hôpitaux, Neurochirurgien, CHU de Poitiers

Remerciements

Je remercie Daniel Bourry (service iconographie, Faculté de Médecine de Tours) pour sa disponibilité et son assistance technique.

Je tiens à remercier également, Brigitte Arbeille et toute l'équipe de microscopie électronique.

Résumé

Les auteurs ont mené une étude anatomique à partir de 20 cadavres. Ce travail a permis d'étudier le concept inter-périostéo-dural appliqué à la région périsellaire en combinant une étude anatomique microscopique et une étude en microscopie électronique des feuillets de la dure-mère. Celle-ci est constituée de deux feuillets : un feuillet ostéo périosté, adhérent à l'os et un feuillet encéphalique au contact du cerveau. Ces deux feuillets sont accolés l'un à l'autre au niveau de la fosse cérébrale moyenne et sont séparés l'un de l'autre au niveau de l'orbite, de la loge caverneuse ou de l'espace épidural rachidien pour former le concept inter périostéo dural. Les feuillets ostéo-périosté et encéphalique ne partagent pas le même aspect en microscopie à balayage au niveau des surfaces. Cette différence d'aspect s'explique par l'histologie des méninges, notamment la nature de l'interface arachnoïde-dure mère. Ces résultats sont importants et démontrent pour la première fois, à un échelon microscopique, la véracité du concept inter-périostéo-dural.

Les angiolipomes sont des tumeurs rares du système nerveux central et se développent essentiellement dans l'orbite, la loge caverneuse et l'espace épidural rachidien. À partir d'une analyse de la littérature et d'un travail anatomique spécifique, axé sur la graisse caverneuse, nous suggérons que l'angiolipome soit la tumeur emblématique du concept inter périostéo-dural.

Mots clés : anatomie, angiolipome, chirurgie de la base du crâne, méninges, microscopie electronique

Abstract

The authors studied the cadaveric heads obtained from 20 adults. We studied by microscopic and ultrastructural methods the extra dural neural axis compartment applied to the perisellar compartment. The dura mater had two dural layers : the endosteal layer, which was firmly attached to the bone and the meningeal layer, which directly covered the brain. These layers joined together in the middle temporal fossa and separated in the orbital, lateral sellar compartment or epidural space to form the extra dural neural axis compartment. The endosteal layer and meningeal layer were not identical on electron microscopy; this result can be readily related to the histology of the meninges. These findings demonstrated the existence of the extra dural neural axis compartment, a notion which has generally been accepted but never demonstrated microscopically.

Angiolipomas are rare tumors of the central nervous system which most frequently develop in the orbit, the cavernous space and the epidural space of the spine. Using data from the published litterature and an experimental anatomic approach, we demonstrated that the cavernous space contains adipose tissue. Consequently, we suggested that angiolipomas constitute the emblematic tumor of the interperiostal dural concept

Key words : anatomy, angiolipoma, skull base surgery, meninges, electron microscopy

Tables des matières

Remerciements **p 2**

Résumé **p 3**

Résumé en anglais **p 4**

Table des matières **p 5**

Introduction **p 6**

Historique du concept interpériostéo-dural **p 7-8**

Embryologie des méninges au niveau de la loge périsellaire **p 9-11**

Le concept inter périostéo dural appliqué à la région périsellaire

Généralités **p 12**

The interperiosteo-dural concept applied to the perisellar compartment: a microanatomical and electron microscopic study. **p 13-31**

The dural sheath of the optic nerve: descriptive anatomy and surgical applications **p 33-50**

Applications pathologiques

Méningiomes de la loge parasellaire **p 51**

Adénomes invasifs **p 52-53**

Lateral sellar angiolipoma : the emblematic tumor of the extradural neural axis compartment **p 55-67**

Perspectives

Etude de l'interface feuillet encéphalique-feuillet ostéo périosté
Après déplétion ou inflation des espaces sous-duraux
Application à l'hypotension intra-cranienne **p 68**

Conclusion **p 69**

Références bibliographiques **p 70-72**

Introduction :

Cette thèse réunit mes travaux publiés et en cours de publication dédiés au concept inter périostéo-dural appliqué à la région périsellaire. Sous la direction de Stéphane Velut, mes travaux ont été mis en œuvre au Laboratoire d'Anatomie de la Faculté de Médecine de Tours et complétés par une approche en microscopie électronique réalisée à partir de la Plate-forme RIO/IBISA de Microscopie électronique (Brigitte Arbeille). Cette thématique de travail s'inscrit dans la continuité des travaux du Laboratoire d'anatomie concernant l'anatomie des méninges. En effet, ces travaux de dissections ont déjà permis d'explorer certaines sous-entités du concept et ont fait l'objet de publications concernant l'anatomie du sac dural hypophysaire, l'anatomie du confluent veineux pétro-clival ou encore l'anatomie des gaines méningées du paquet acoustico facial.[8,9,19-21] Ces différents travaux s'intègrent dans une conception plus générale de la dure-mère : le concept inter périostéo dural. L'originalité de ce travail a été de démontrer à un échelon microscopique ce concept largement accepté mais non démontré, à ce jour. Cette évolution conceptuelle de la dure-mère périsellaire est rappelée dans un court chapitre historique, l'embryologie de la région est succintement décrite.

Evolution des définitions et des conceptions

Depuis la description princeps des méninges par Vésale[34], les données concernant la loge parasellaire ont évolué. C'est Ridley[29] en 1695 qui est le premier à décrire un espace veineux entourant la carotide interne de part et d'autre du sphénoïde.
Winslow[36] en 1732 constate la présence de trabéculations fibreuses et propose la dénomination de sinus caverneux par analogie avec les corps caverneux du pénis. Taptas[31] et Bonnet[4] apportent une conception plus moderne des parois du sinus caverneux et introduisent la notion d'espaces inter périostéo-duraux. Ils expliquent que les enveloppes cérébrales sont constituées de leptoméninge, de dure-mère et d'os crâniens. Taptas[31] utilise l'embryologie pour expliquer qu' avec le « développement du cerveau, il se forme des replis qui n'intéressent que le feuillet dural propre et dont les deux principaux sont l'un vertical (faux du cerveau) et l'autre horizontal (tente du cervelet) ». En appliquant ce principe au niveau de la région périsellaire le sinus caverneux devient un espace interpériostéo-dural. Le feuillet « propre » correspond au feuillet encéphalique et forme les parois latérale, supérieure et le sac dural hypophysaire alors que le périoste correspond au feuillet ostéo periosté qui tapisse le sphénoïde. Les loges caverneuses sont alors décrites comme un espace interpériostéo dural communicant entres elles avec l'orbite mais également avec le confluent veineux pétro clival comme l'a démontré Destrieux, et al.[9] Depuis la description de Taptas[31], les différentes parois de ce sinus caverneux ont fait l'objet de nombreuses études anatomiques.[5,15,16,27,33,38]
Parkinson[23-26] généralise cette conception de la région parasellaire à l'ensemble du névraxe et le concept inter périostéo dural, véritable continuum anatomique étendu du coccyx à l'orbite est décrit. Le feuillet encéphalique est représenté par la gaine durale du nerf optique, les parois latérale, supérieure et supéro-médiale de la loge parasellaire et le fourreau dural qui contient la moelle épinière. Le feuillet ostéo périosté est représenté par le périorbite, la paroi inféro-médiale de la loge caverneuse et le périoste vertébral. Les espaces inter périostéo dural rachidien, orbitaire et parasellaire contiennent des lacs veineux et de la graisse dont la finalité est de faciliter les mouvements de glissement entre ces feuillets.

Cette description du concept inter-périostéo-dural est largement admise à ce jour et reste très utilisée pour l'abord extradural de la loge caverneuse, de l'orbite ou de la loge trigéminale.[23,40] Pourtant ce concept n'a, à ce jour, jamais encore été démontré à un échelon microscopique. Le but de ce travail a été de démontrer cette conception des méninges en reprenant une série de dissections microanatomiques et en complétant ce travail par une analyse des surfaces des feuillets en microscopie à balayage. L'originalité de ce travail a été de mettre en évidence que les différents feuillets de la dure-mère n'ont pas le même aspect. Le feuillet encéphalique est constitué d'un maillage de collagène recouvert d'un matériel amorphe. Ce dernier est largement décrit dans la littérature et correspond en fait à une zone de moindre résistance, située dans l'épaisseur même du feuillet encéphalique.[12,14,22] Lorsque le feuillet encéphalique est prélevé, le plan de clivage passe par cette zone de moindre résistance et l'on ne prélève donc pas à proprement parlé le feuillet encéphalique dans toute son épaisseur mais seulement la partie la plus externe. Le feuillet profond du feuillet encéphalique reste adhérent à l'arachnoïde car ces cellules sont connectées par des jonctions intercellulaires puissantes de type tight junction. Le feuillet superficiel correspond au feuillet encéphalique supposé prélevé montrant ce matériel amorphe. Cette conception du feuillet encéphalique et de zone de moindre résistance n'est pas récente et est largement décrite dans les travaux de Friede et al.[13], Schachenmayr et al.[30], Frederickson[12] et Haines[14].

Embryologie et ultrastructure des méninges

Le développement des méninges au niveau de la région périsellaire est complexe et peut être subdivisé en trois périodes selon les travaux de Tobenas-dujardin et al.[32] réalisés à partir de coupes histologiques sériées sur 39 embryons couvrant les six premiers mois de la vie embryonnaire :

- Une période d'organogénèse s'étendant sur les quatre premières semaines de gestation
- Les premières semaines de la vie fœtale où se met en place la loge parasellaire et son contenu.
- Une période s'étendant du quatrième mois à la fin de la vie fœtale où ces éléments installés se développent.

Au stade 7 mm, l'embryon est constitué dorsalement par le métencéphale qui contient le quatrième ventricule, médialement l'ébauche hypophysaire, ventralement le diencéphale et les voies visuelles, latéralement le ganglion trigéminal. La période embryonnaire permet la mise en place du contenu vasculo-nerveux de la loge parasellaire notamment le ganglion trigéminal et ses branches.

Au stade 14,5 mm, il n'est pas possible de distinguer une paroi médiale séparant l'hypophyse de la loge parasellaire. A ce stade une différenciation méningée apparaît autour des différentes vésicules cérébrales .

Au stade 15,5 mm-18 mm, la loge parasellaire voit son contenu se modifier avec l'apparition de parois vasculaires autour des veines et une diminution du volume sanguin veineux. Les parois méningées de la loge parasellaire ne sont toujours pas différenciées.

Au stade 23,5-25 mm, l'hypophyse est séparée des loges parasellaires par une capsule et le diaphragme sellaire apparaît comme une extension de la tente du cervelet. Il n'y a pas encore à proprement parler de paroi médiale de la loge parasellaire et ces deux loges communiquent très largement entre elles. De même, les loges parasellaires communiquent largement avec les cavités orbitaires et de la graisse apparaît. Alors que l'hypophyse est contenue dans une capsule hypophysaire, il est impossible d'individualiser de la méninge entre la capsule hypophysaire et la loge parasellaire.[6,7] La paroi latérale de la loge parasellaire est constituée par le ganglion trigéminé autour duquel il devient possible d'individualiser une gaine durale. La loge latéro sellaire est constituée de trois plans : un plan artériel

médial accompagné du VI, un plan veineux intermédiaire et un plan nerveux latéral. Ces éléments sont situés entre les vésicules cérébrales en haut et rostralement, entourées des méninges, et les futurs cartilages formant la base du crâne. Les nerfs III, IV sont recouverts d'une couche pluricellulaire (membrane limitante méningée) appartenant à la future arachnoïde. Le segment extra-méningé de ces nerfs est entouré de mésenchyme interposé entre les méninges et les ébauches cartilagineuses de la base du crâne. Cette constatation rejoint les travaux de Taptas[31]. L'espace interpériostéo-dural apparaît, limité par le ganglion trigéminal et ses branches, il contient le VI, la veine céphalique primitive et la veine prootique qui participeront au plexus veineux parasellaire. Le toit de la loge parasellaire apparait à partir d'une extension latérale de la tente du cervelet.

Au troisième mois, alors que l'organogénèse est terminée, la période fœtale débute et les constatations sont inchangées. A la quinzième semaine (date critique pour la constitution des loges caverneuses), il devient possible d'individualiser une seconde couche cellulaire autour de la capsule hypophysaire correspondant au sac dural hypophysaire, suspendu au diaphragme sellaire.

Les parois médiale et latérale de la loge parasellaire apparaissent à la quinzième semaine d'aménorrhée et ne se modifient plus par la suite. La paroi médiale est composée dans sa partie crâniale par la loge hypophysaire et dans sa partie caudale par le périoste du sphénoïde. La paroi latérale est constituée de deux couches méningées : une couche externe, solide en continuité avec la fosse cérébrale moyenne et une couche interne correspondant à l'apposition des gaines durales des nerfs ophtalmique, trochléaire, oculo-moteur. Au 7éme mois, la dure mère et l'arachnoïde sont différenciées et s'invaginent l'une et l'autre pour accompagner les nerfs sur une partie de leur trajet. Ces gaines méningées contiennent du liquide cérébro-spinal.[17]

Concernant l'ultrastructure des méninges, il est possible de différencier les trois feuillets méningés classiquement décrits par Bichat[3] à partir du troisième mois de développement chez le foetus humain. Dés ce stade, les cellules arachnoïdiennes constituent une couche cellulaire compacte à la périphérie de l'espace sous-arachnoïdien. Leur aspect est unique et homogène : ce sont des cellules à noyaux clairs reliées par de nombreux systèmes de connexions intercellulaires. À partir du 7° mois, les cellules arachnoïdiennes peuvent être distinguées en deux sous

populations : les cellules superficielles sombres au contact de la dure mère et les cellules internes, plus claires au contact de la pie-mère.

La dure-mère est composée de deux feuillets différents : un feuillet ostéo périosté et un feuillet encéphalique. Le feuillet ostéo périosté est composé principalement de collagène, agrégé en lamelles et faisceaux épais denses qui sont obliques les uns par rapport aux autres. On y trouve également des fibres élastiques. Les cellules de cette couche sont de type fibroblastique. En accord avec les travaux de Haines et al.[14] ce feuillet est très adhérent à l'os du crâne. Le feuillet encéphalique est composé d'une population cellulaire plus dense de type fibroblastique, se situant au sein d'un tissu conjonctif organisé en couches de faisceaux de collagènes orientés. Il est limité en profondeur par plusieurs assises de cellules aplaties, mal différenciables en microscopie optique, des cellules de la couche la plus superficielle de l'arachnoïde. Les fibroblastes les plus internes de ce feuillet encéphalique sont solidement attachés à la partie externe de l'arachnoïde. De fait, l'espace sous-dural n'existe pas et correspond à un espace virtuel de moindre résistance dans l'épaisseur du feuillet encéphalique. L'hématome sous-dural classiquement décrit n'a aucun support histologique et correspond à un hématome inter-dural formé dans l'épaisseur du feuillet encéphalique.[13,30] C'est ce feuillet qui forme la coque externe de cet hématome.

Le concept inter-périostéo-dural appliqué à la région périsellaire

Pour réaliser ce travail nous avons utilisé 20 extrémités encéphaliques préparés selon des modalités différentes en fonction de l'étude réalisée. 4 préparations ont été utilisées pour la microscopie électronique. 3 préparations ont été réalisées de façon à pouvoir ramollir les structures osseuses autorisant ainsi la réalisation de coupes coronales (coupant l'os) sans dénaturer le contenu graisseux intra-caverneux. Ces préparations ont permis de décrire l'architecture meningée de la loge caverneuse dans un plan coronal, peu utilisé à ce jour compte tenu de l'environement osseux de la région. 13 préparations ont été utilisées pour les dissections anatomiques sous microscope opératoire des différents feuillets de la dure-mère au niveau de la région périsellaire.

Le choix de compléter ce travail par une approche en microscopie électronique à balayage au niveau des surfaces et des tranches est lié au fait que l'étude en microscopie optique ne permettait pas de distinguer la structure de ces feuillets. En effet, malgré la multiplicité des colorations utilisées (Hématoxyline Eosine Safran, coloration au rouge Sirius, coloration de Wilder, coloration de Jones), il ne nous a pas été possible de différencier ces feuillets, la structure collagénique de ceux-ci étant superposable. La première partie de ce travail concerne la description du concept inter-périostéo-dural avec cette approche anatomique double : macroscopique et microscopique des feuillets de la dure-mère sous la forme d'une publication, acceptée dans la revue **Journal of Neurosurgery**.

Ce travail est consolidé par une seconde étude anatomique axée sur la gaine durale du nerf optique, prolongement rostral du concept inter-périostéo-dural avec la même approche (dissection-microscopie électronique). Ce travail est accepté pour publication dans la revue **Advances and Technical Standards in Neurosurgery**.

The interperiosteo-dural concept applied to the perisellar compartment: a microanatomical and electron microscopic study.

PATRICK FRANÇOIS[1,2], M.D., NADINE TRAVERS[1,2], M.D., EMMANUEL LESCANNE[3], M.D., Ph.D, BRIGITTE ARBEILLE[4], Ph.D., MICHEL JAN[2], M.D., STEPHANE VELUT[1,2], M.D., PH.D.

(1) Université François Rabelais de Tours, Laboratoire d'anatomie, Tours, France
(2) CHRU de Tours, Service de Neurochirurgie, Tours, France
(3) CHRU de Tours, Service d'Oto-Rhino-Laryngologie, Tours, France
(4) Université François Rabelais de Tours, Département de Microscopie Electronique, Tours, France

KEY WORDS : cavernous sinus, dura mater, meninges, anatomical study, skull base surgery

Abbreviations used in this paper: EDNAC = Extra Dural Neural Axis Compartment; LSC = Lateral Sellar Compartment; ML= Meningeal Layer; EL = Endosteal Layer; CN = Cranial Nerve

Abstract

Object. The authors studied the cadaveric heads obtained from 13 adults. Ten of the specimens were injected with colorated latex and the 3 other specimens were studied by microscopic and ultrastructural methods in order to describe the Extra Dural Neural Axis Compartment (EDNAC) in the perisellar area. Special attention was paid to the dural layers surrounding the perisellar area. The aim of this work was to anatomically verify the concept of the EDNAC by using electron microscopy.

Methods. We injected ten cadaveric heads (or 20 perisellar areas) with colorated latex and fixed them in formalin. We cautiously removed each brain in order to allow a superior approach to the perisellar area. We studied the anatomy of the meningeal architecture of the lateral sellar compartment (LSC), the petroclival venous confluence, the orbit and the trigeminal cave and following dissection, took photographs of the dural layers with the aid of optic magnification. The three remaining heads, obtained from fresh cadavers, were prepared for electron microscopic study.

The dura mater had two dural layers: the endosteal layer (outer layer), which was firmly attached to the bone and the meningeal layer (inner layer), which directly covered the brain. These two dural layers joined together in the middle temporal fossa or the convexity and separated in the orbital, lateral sellar compartment or spinal epidural space to form the EDNAC. This EDNAC was limited by the endosteal layer and the meningeal layer and contained fat and/or venous blood. The EL and ML were not identical on electron microscopy; this finding can be readily related to the histology of the meninges.

Conclusions. In this study, the authors demonstrated the existence of the EDNAC concept in the perisellar area by using dissected cadaveric heads and verified the reality of the concept in the meningeal layer with electron microscopy. These findings clearly demonstrated the existence of the EDNAC, a notion which has generally been accepted but never demonstrated microscopically.

The meninges enclosing the central nervous system have generally been considered to consist of 3 different layers: the outermost layer or dura mater, the intermediate layer or arachnoid mater, and the innermost layer or pia mater. The dura mater forms the outer meninge and covers the spine and the brain. [27,33] Taptas's work on the cavernous sinus [29] has significantly improved our knowledge of the descriptive anatomy of the dura; in particular, he was the first to show that the lateral sellar compartment (LSC) is an extradural space which contains venous blood, fat, the carotid artery and the sixth cranial nerve. Since then, the lateral, medial and superior walls of the cavernous sinus have been thoroughly described. [3,14,26,32,36] Parkinson has integrated the anatomy of the LSC into an anatomical concept, the extradural neural axis compartment (EDNAC), which extends from the coccyx to the orbit.[24,25]

The dura mater lining the internal surface of the calvaria is formed by two layers: the outer or endosteal layer (EL), which is thin and strongly attached to the bone and the inner layer or meningeal layer (ML), which is thick and directly covers the brain.[12] The ML and the EL are closely adherent in the middle cranial fossa, but in the LSC (middle part of the EDNAC), the ML forms the lateral wall of the cavernous sinus which is doubled medially by the apposition of the third, fourth and ophthalmic nerve dural sheathes.[23,29,32] According to Destrieux, this ML forms the pituitary dural bag around the pituitary gland and lies below the diaphragm to form the medial wall of the cavernous sinus.[8] The EL covers the sphenoid bone. The inter-periosteo-dural space [29] is located between the EL and the ML. The orbital segment of the inter-periosteo-dural space is the rostral part of the EDNAC and lies between the EL (periorbita) and the ML (optic dural sheath). Consequently, the orbital compartment is an extradural space which contains fat (to facilitate movements), venous blood, muscles and the cranial nerves implicated in eye mobility.[34] The spinal compartment of the inter-periosteo-dural space extends between the periosteum (EL) which covers the vertebral bone and the ML which contains the spinal cord. These layers demarcate the epidural space containing fat and epidural veins.[24] This space is the caudal part of the EDNAC.

The EDNAC is a generally accepted concept, especially by skull-base neurosurgeons but it has never been demonstrated microscopically. The aim of this work was to demonstrate the reality of this concept by focusing on the perisellar compartment using microanatomical cadaver dissections and to provide microscopic proof based on electron scan studies.

Materials and Methods

We studied cadaveric heads from 13 adults (or 26 perisellar areas) by performing microdissection and electron microscopy. For the microanatomical study, we injected the blood vessels in 10 cadaveric heads with colored neoprene latex, using red for the internal carotid and vertebral arteries and blue for the jugular veins. The specimens were fixed with a 10%-formalin solution. Among these 10 cadaveric heads, 2 were injected as above and subsequently bleached with a 20%-hydrogen peroxide solution. After several weeks, this procedure produced softening of the bone without modifying the fixed, soft tissues, thus allowing the bone to be cut with an ordinary scalpel, thereby permitting coronal dissections. Cautious removal of the skull vault and brain of the skull base allowed us to use a superior approach to the parasellar area. Dissections were performed with the aid of optic magnification (250-300 and 400-mm focal distances). The dural layers were progressively dissected in order to clearly identify the dura mater within the parasellar area. We used 3 fresh (<24 hr.) cadaveric heads for the scanning Electron Microscopy study. We removed the dural bag around the pituitary gland, the dural sheath of the optic nerve, the lateral wall of the LSC, the dura mater which covers the clivus and the periorbita with the help of optic magnification. The samples obtained were correctly orientated and fixed in 1%-glutaraldehyde, 4 %-paraformaldehyde in 0.1 M phosphate buffer (pH 7.4), post-fixed in 2 % osmium tetroxide, dehydrated in a graded ethanol series, critical point-dried using carbon dioxide and coated with gold sputtering, as previously describe.[20]

Sources of supplies and equipment

The surgical microscope (model OPMI 9FC) we used was manufactured by Zeiss (Oberkochen, Germany). The Nikon camera (FE) and Kodak film (Ektachrom 160T) were purchased from Nikon (Tokyo, Japan) and Eastman Kodak (Rochester, NY), respectively. We used a GEMINI 982 LEO (Oberkochen, Germany) Scaning Electron Microscope for scanning electron microscopy. The Hasselblad camera and lenses were purchased from Victor Hasselblad AB (Göteborg, Sweden). The RSX100 120 roll-film was manufactured by Agfa-Gevaert S.A (Rueil-Malmaison Cedex,

France). The neoprene latex (#671) injected into the vessels of the cadaveric heads was manufactured by E.I. Du Pont de Nemours-Dow Elastomers (Wilmington, DE)

Results

The LSC (Fig. 1 ABCDEF)

The LSC formed the middle part of the EDNAC. The lateral wall of the LSC was formed by the apposition of two meningeal layers: the outer layer which was a continuity of the ML covering the middle crania fossa and the inner layer which was formed by dural sheathes surrounding the cranial nerves and which coursed along the lateral wall of the LSC to reach the orbit. The dural sheath of the oculomotor nerve was clearly evident on the coronal section passing through the LSC (Fig.1A). The trochlear dural sheath and the ophthalmic dural sheath, demarcating Parkinson's triangle [23] , were found below the dural sheath of the third cranial nerve. The medial wall of the LSC was formed by the dural bag surrounding the pituitary gland. Laterally, the pituitary gland can be described as a tongue-like extension above the horizontal segment of the carotid artery. The ML which covered the sphenoidal planum extended caudally to form the diaphragm sellae and the pituitary dural bag (Fig. 1C). After opening the pituitary dural bag and partially removing the pituitary gland (Fig. 1 E), the anterior and posterior coronary sinuses were exposed between the LSCs. These trans-sellar connections between the LSCs may exist at any point from the anterior to the posterior wall of the sella and are named on the basis of their relationship to the pituitary gland. The floor of the LSC was formed by the EL which covered the sphenoid sinus (Fig. 1A). The posterior portion of the roof of the LSC was formed by a layer of ML between the lateral wall of the LSC and the diaphragm sellae. The oculomotor dural sheath was formed by an evagination of the dura mater at this level (Fig. 1A). The anterior roof of the LSC was more complex; in order to study it, the anterior clinoïd process had to be drilled to expose the anterior clinoid space (Fig. 1D) which is a virtual space that is filled with the clinoid process in undisturbed crania. The carotid oculomotor membrane was located between the oculomotor dural sheath and the carotid artery. The proximal and distal dural rings demarcated the clinoid segment of the carotid artery and were formed by a reinforcement of the carotid oculomotor membrane around the carotid artery (Fig. 1D). The carotid artery described its cavernous segments below the proximal dural ring (lower ring). As previously described by Inoue et al., [15] the intracavernous carotid

artery was divided into five segments. The posterior vertical segment was the proximal part of the artery, the second part was the posterior bend, the third part was the horizontal segment (Fig 1C), the fourth part was the anterior bend and was continued by the anterior vertical fifth segment. The carotid artery penetrated the subarachnoïd space above the distal dural ring (upper ring). The optic strut was a bridge of bone that separated the optic canal from the superior orbital fissure and extended between the optic and oculomotor nerves (Fig. 1B). The anterior clinoid space was covered by the ML. This continuous horizontal layer spreading between the two anterior petroclinoid folds (dural folds that connect the petrous apex with the anterior clinoid process) formed the roof of the LSC laterally, and on the midline formed the diaphragma sellae which is pierced by the diaphragmatic foramen containing the pituitary stalk.

The orbit (Fig.1B)

The orbital compartment was the rostral part of the EDNAC. This extradural space lay between the dural sheath of the optic nerve and the periorbita. Arteries, veins, muscles and nerves were embedded in abundant adipose tissue. The oculomotor, trochlear and ophthalmic nerves converged at the superior orbital fissure. Beneath the *periobita*, the fat had to be removed in order to expose the trochlear nerve which passed above the levator muscle to reach the superior oblique muscle. The frontal nerve arose from the ophthalmic nerve and entered the orbit by passing through the lateral part of the superior orbital fissure, lateral to the annular tendon before dividing into the supratrochlear and supraorbital nerves. The lacrymal nerve coursed along with the lacrymal artery beneath the periorbita and above the lateral *rectus* muscle and reached the lacrymal gland laterally (Fig. 1B). The optic dural sheath enclosed the optic nerve in the optic canal and was formed by a layer of the ML at the level of the optic canal. The falciform ligament appeared to be a dural fold extending from the anterior clinoid process to the *tuberculum sellae* which formed the cranial part of the optic dural sheath. The annular tendon lay in front of the superior orbital fissure and the optic canal. The four *recti* muscles arose from the annular tendon while the levator muscle arose from the lesser wing of the sphenoid; the superior oblique muscle ran from the body of the sphenoid dorsally to the optic

canal. The optic dural sheath formed the central part of the orbit and reached the globe to form the *sclera*.

The petroclival venous confluence (Fig 1F)

The petroclival venous confluence covered the clivus and contained the interdural venous confluence. There were fibrous trabeculations between the EL and the ML limiting this space; these trabeculations created small holes in the blue latex filling the venous space (Fig. 1F). This space was limited laterally by the LSC and was crossed by the abducens nerve which was located in Dorello's canal.[10] The abducens nerve pierced the upper part of the clivus, crossed the petroclival venous confluence, then passed beneath the petrosphenoidal ligament of Grüber to reach the LSC and the superior orbital fissure (Fig. 1C). The petrosphenoidal ligament of Grüber appeared to be a fibrous bundle extending from the apex of the petrous bone to the posterior clinoid process (Fig. 1F). In agreement with Destrieux's work,[7] the sixth cranial nerve's dural sheath was formed by the ML; it accompanied the nerve to the LSC. The petroclival venous confluence was located between the EL and the ML of the clivus. It drained the cavernous sinus, the superior petrosal sinus, the basal sinus of the clivus and emptied into the inferior petrosal sinus and the jugular bulb. The petroclinoid venous confluence formed the middle part of the EDNAC between the LSC and the spinal compartment.

The trigeminal cave (Fig 2 ABC)

The trigeminal cave contained the sensory and motor roots of the trigeminal nerve, the gasserian ganglion, and the arachnoid cistern. The trigeminal cave is a dural pocket beneath the dura mater of the middle cerebral fossa; within it, the posterior and motor roots of the trigeminal nerve fit like "a hand in a glove" (Fig. 2C). The trigeminal cave's floor was formed by the apposition of the EL and the ML. The roof was formed by a doubling of the EL of the middle cerebral fossa (Fig. 2A, 2C). The ML of the middle cerebral fossa curved onto the anterior petroclinoid fold (free edge of the tentorium) to form the inner layer of the roof of the trigeminal cave (Fig.2C). The superior petrosal sinus, which emptied into the LSC by passing above the trigeminal nerve (Fig. 2B, 2C), was lying between these two layers. The motor root arose rostral to the sensory root and passed through Meckel's cave on the medial side of the posterior sensory root and ganglion. At the anterior convex margin

of the gasserian ganglion, the ML of the trigeminal cave became the epineural sheath of each division of the trigeminal nerve. The ophthalmic nerve and its dural sheath reached the lateral wall of the LCS and the orbit below the oculomotor and trochlear nerves. The maxillary nerve and its dural sheath exited the skull through the foramen *rotundum*. The mandibular nerve reached the foramen *ovale* to join with the infra-temporal fossa. The cleavage plane between the ML on the dorsal part of the trigeminal's cave continued rostrally at the level of the epineural sheaths of the trigeminal nerve divisions and served as the anatomical basis for the interdural exposure of the contents of Meckel's cave.[1,38]

Electron microscopy (Fig. 3, 4, 5)

The petroclival sinus (Fig. 3ABC)

The EL and ML of the dura contained an extensive amount of extracellular collagen. The EL was firmly attached to the clivus. The ML was separated from the EL by venous blood which formed the petroclival venous confluence. On transverse section, the EL and ML were similar with a regularly-aligned collagen fibre orientation. The ML was thicker than the EL and the collagen bundles of both layers were arranged in a well-ordered network (Fig. 3B). The petroclival venous confluence is the portion of the EDNAC situated between the LSC and the spinal compartment. It contains venous blood from the LSC and the superior petrosal sinus and empties into the jugular bulb. The abducens nerve pierces the ML, which forms its dural sheath, and reaches the LSC between the EL and the ML.

The pituitary dural bag (Fig. 4ABCDE)

The ML covering the planum wrapped it caudally to form the pituitary dural bag. The diaphragm was in fact an extension between the ML of the anterior cranial fossa and the pituitary dural bag (Fig. 4A). The pituitary dural bag containing the pituitary gland was attached to the inferior aspect of the *diaphragma sellae* and was comprised by an evagination of the ML into the *sella* which extended to the diaphragmatic foramen. The pituitary gland was covered by the pituitary capsule (Fig. 4B), which attached to the pituitary dural bag. The pituitary capsule is a thin semitransparent membrane that adheres closely to the gland. On transverse section, the ML of the *planum* and the pituitary dural bag had the same thickness (Fig. 4DE) and were formed by a network of collagen bundles.

EL and ML (Fig. 5ABCDEF)

We removed most of the dural layers constituting the EDNAC in the perisellar compartment and closely studied them. The inner layer of the dura which covered the clivus (D), the *periorbita* (E) and the floor the LSC (F) corresponded to the EL whereas the outer layer of the clivus (A), the optic dural sheath of the optic nerve (B) and the lateral wall of the LSC (C) corresponded to the ML. The EL and ML of the dura mater were comprised by densely arranged extracellular collagen oriented in various directions. The ML was covered (black arrowheads) by extracellular, filamentous, amorphous, electron-dense material. We never observed this aspect in the EL. We didn't observe any cells or cell membranes on these layers like those seen in the dural border cells.[12] We consistently found this same significant result in each sample.

Discussion

The inter periosteo-dural concept, which is called the extradural neural axis compartment since Parkinson's description [24,25], is an anatomic complex which extends from the coccyx to the orbit. It contains valve-less veins and adipose tissue which facilitate eye movements and spinal dura which is especially abondant in the spine and orbit. The orbital compartment lies between the periorbita and the optic dural sheath. The LSC was located between the EL which covered the sphenoid bone, and the ML which formed its upper and lateral wall and the pituitary dural bag. The caudal portion of the EDNAC extended from the EL covering the spine to the ML, which contained the spinal cord. According to Arnautovic, et al., [2] there are a number of anatomical similarities between the sub-occipital region and the LSC, in particular venous cushioning and the anatomical properties of the vertebral and carotid arteries in this compartment with their loops, branches, dural rings, and dural architecture. The meningeal structure of the LSC has been well-described during the past 40 years [14,15,17,30,32] using microsurgical dissection on cadavers. However, only a few descriptions focus on the meningeal architecture of the LSC.[16,19,36] To the best of our knowledge, the EDNAC has never been clearly demonstrated using an electron scan study. The EL and ML are not identical: notably, the EL is characterized by a large amount of collagen bundles while the ML is formed by a network of collagen fibres covered by an amorphous material (Fig. 5). In order to better understand this

morphology, we have to focus on the histological structure of the meninges. The dura mater consists of two portions: an outer, endosteal layer forming the periosteum of the inner table of the skull, and an inner, fibrous or meningeal layer.[12,13] The cranial fibrous dura mater consists of a lamination of fibroblasts oriented parallel to the skull with layers of collagen fibers between them. Microfibrils and elastic fibers may also be present but in significantly smaller amounts than collagen.[28] The dura immediately adjacent to the EL of the skull is made up of plump osteoblasts and osteoclasts, rich in calcium, which coat the adjacent collagen fibers (Fig. 3A).The ML is formed by the apposition of the meningeal dura and the dural border cells. This aspect was first described by Nabeshima et al.[22] The transition between the dural border cells and the meningeal dura is characterized by the appearance of loosely distributed collagen fibrils and a large amount of fuzzy extracellular material in the greatly dilated extracellular space. The dural border cells have no extracellular collagen, few cell junctions, and an enlarged extracellular space filled with an amorphous material which is described as being granular and fuzzy.[12,21] The junction between the dural border cells and the meningeal dura is characterized by a decrease in this amorphous material and an increase in collagen fibers. In addition, the dural border cells are firmly attached to the arachnoid barrier layer which can be distinguished from the underlying arachnoid by the compact arrangement of its cells and by the basement lamina, which separates its inner surface from the collagen of the arachnoid (Fig. 6). The layer of dural border cells is attached to the arachnoid barrier layer by a few cell junctions. The dural border cells are the weakest plane in the meninges.[11] Finally, we failed to identify any subdural space at the interface between the arachnoid and dura as has been previously described.[21] Hayne's review [12] , which was based on Frederickson's work, [11] summarized our knowledge on the dura-arachnoid junction. Accordingly, he mentioned that the line of least resistance passes through the dural border cells and that the subdural space doesn't occur spontaneously but is the direct result of tissue damage. The dura and arachnoid are attached to one another and anchored in opposite directions. The EL is attached to the skull and the arachnoid is anchored to the brain. The removal of the ML along the weakest plane, referred to above, exposes the dural border cells and the amorphous materials contained in the extracellular compartment. This cleavage plane doesn't exist spontaneously; it may be the consequence of an opening in the dura since the strain placed on the meninges when the dura is elevated can be relieved by a tear

which occurs along the cleavage plane in the dural border cells. Furthermore, this phenomenon occurs in subdural hematomas since there is no natural space between the dura and the arachnoid. Venous blood coming from a tear in the wall of traversing veins dissects the dural border cell layer to form subdural hematomas .[28] This may explain our findings concerning the superficial aspect of the EL and ML and corroborates present knowledge on the distribution of the EL and the ML in the EDNAC.

The existence of the EDNAC is a generally accepted concept although certain details concerning the medial wall of the LSC remain controversial.[9] The medial wall of the LSC corresponds to the lateral part of the pituitary fossa and forms the only border between the pituitary fossa and the contents of the LSC. This border may constitute a barrier to tumor spread into or coming from the LSC. In contrast to the two layers of ML that we observed in the lateral and superior walls of the LSC, our microsurgical anatomic study demonstrated that the medial wall is formed by a single dural layer which is a continuation of the upper layer of the diaphragm sellae (Fig. 1 ACE). These findings were confirmed by the results of our electron scan study (Fig. 4 AC). On sagittal section (Fig 4C), the ML covering the anterior cranial fossa curved at the level of the diaphragm to form the pituitary dural bag. On transverse section, the pituitary dural bag was identical to the ML of the anterior cranial fossa (Fig. 4DE) and had the same density of collagen bundles. Furthermore, the pituitary dural bag is strengthened by a collagenous layer, the pituitary capsule (Fig. 4B). The pituitary capsule is a thin, translucent layer of connective tissue covering the surface of the pituitary gland although it is different from the dura layer lining the sella turcica. The pituitary capsule may derive from the pia mater [5] or from the mesenchymal cells [4] located around the developing ante-hypophysis. The pituitary dural bag isolates the hypophysis from all surrounding structures, particularly the LSC. According to Destrieux et al.,[8] the pituitary dural bag extends laterally above the carotid artery in 29% of the cases and can mimic tumor invasion in the cavernous sinus when an adenoma occurs in the lateral expansion of the pituitary dural bag. The pre-operative diagnosis of LSC invasion by pituitary adenomas has been the subject of several studies [6,18] since LSC invasion is the most common limiting factor in the resection of these tumors. Despite their benign histological nature [31] , these adenomas can become quite aggressive and even invasive. The pituitary dural bag presents a significant weakness in comparison to the superior and lateral walls of the LSC.

Yokoyama et al.[37], described small histological defects in the medial wall of the LSC through which adenomas may extend laterally. The presence of these defects may explain the discrepancy between the benign histological nature of pituitary adenomas and their frequent extension into the LSC. These results are in agreement with Kawase's work [16] on the meningeal architecture of the LSC. The LSC is protected against tumor invasion from the exterior by both meningeal layers of the lateral wall. Tumors located in the LSC may extend elsewhere through meningeal weak-points located in the medial wall of the LSC, the meningeal pockets of the III and V cranial nerves, or the cavernous apex. The medial wall of the LSC is a thin structure which is not visible on MR imaging; it is therefore not helpful for diagnosing invasion with MRI.[6,9] Nevertheless, using high-field, high-resolution magnetic resonance imaging (3 tesla magnetic resonance imaging), Wolfsberger et al.,[35] has reportedly been able to observe the medial wall of the LSC in the form of a hypointense line on T1-weighted contrast enhancement. This permitted him to diagnose LSC invasion by pituitary adenomas in 84% of 3-tesla MRIs compared with 59% using standard magnetic resonance images. The medial wall of the LSC appears as a discrete line compared to the lateral wall of the LSC. This may be explained by the fact that the sellar portion of the medial wall is formed by a single layer of dura doubled by a pituitary capsule which covers the pituitary gland.

Conclusions

We present the anatomical meningeal features of the parasellar compartment in detail. Good knowledge of the surgical anatomical features of this region is important for the surgical management of paraclinoid aneurysms and neoplasms. The EDNAC concept is a accepted notion in the medical community. The EL and the ML have different superficial aspects which can be explained by the histological relationships between dural border cells and arachnoid barrier cells.

The medial wall of the LSC is very important for surgeons because it limits the pituitary dural bag laterally and the LSC medially. This medial wall is formed by two connective layers: a dural layer which forms the pituitary dural bag and a connective layer which forms the pituitary capsule.

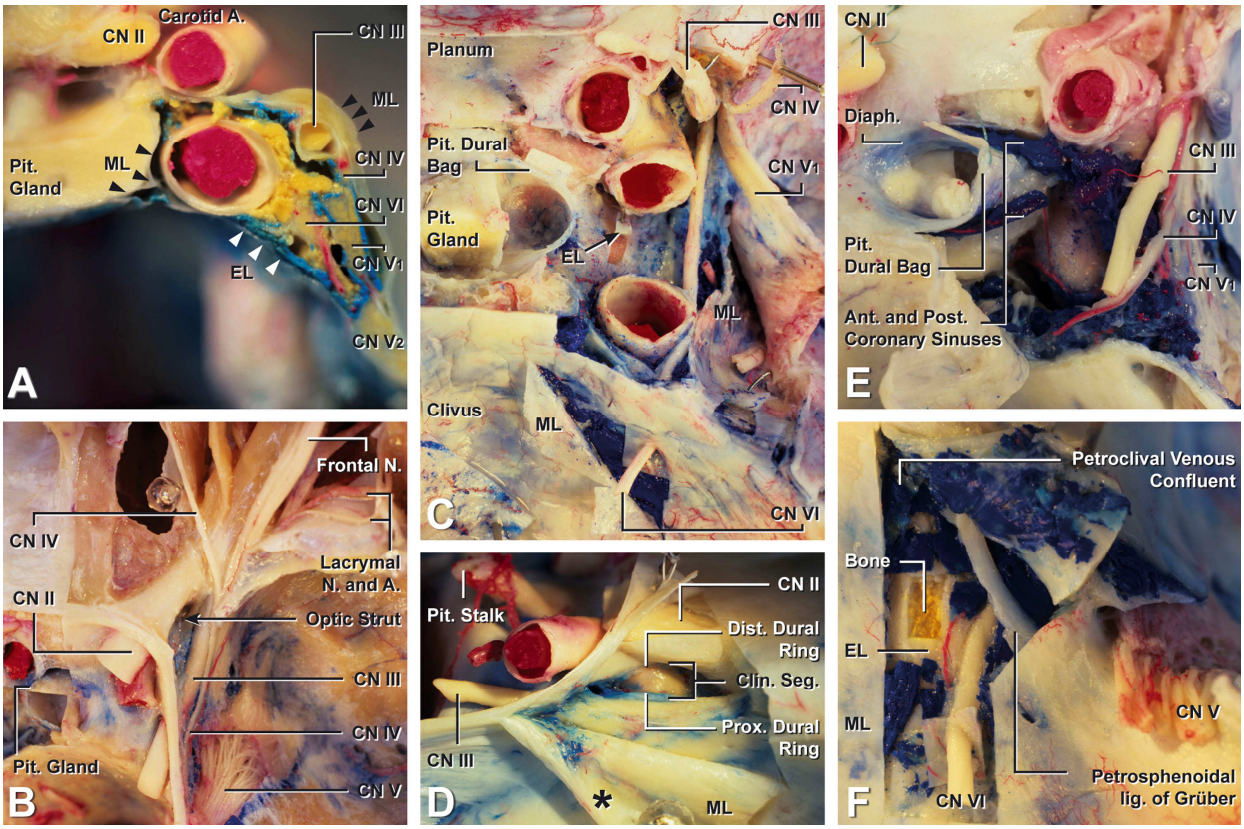

Figure 1 :

A : Coronal section passing through the LCS. The medial wall of the LSC (hypophyseal dural bag) has been exposed (arrrows). CN III, IV, V1 dural sheathes are exposed in the lateral wall of the LSC. The LSC contained fat, venous blood, the carotid artery and the CN VI. The ML of the lateral wall of the LSC are exposed (black arrowheads). The EL which formed the floor of the LSC is individualised (white arrowheads). **B** : Superior view of the perisellar area. The orbital roof has been drilled and the periorbita opened to expose the orbital apex. The anterior clinoid process has been drilled; CN II and III were dissected and delimited a dural spread: the carotido-oculomotor membrane which lies between the carotid artery and the CN III dural sheath. The ML of the middle fossa has been incised to expose the lateral wall of the LSC. CN III, IV, V1 exited the skull and reached the orbit passing through the superior orbital fissure. **C** : Superior view of the right LSC: The ML, which formed the superior and lateral wall of the LSC, has been removed. The floor of the LSC was formed by the EL which covered the sphenoid bone. The lateral portion of the pituitary gland has been resected to expose the dural bag around the hypophysis. The CN VI was lying in the petroclival venous confluence and reached the LSC and the superior orbital fissure. **D** : Lateral view of the right LSC. The anterior clinoid space has been exposed. The outer layer of the lateral wall of the LSC has been incised (*). The carotid-oculomotor membrane formed the proximal and distal dural rings around the clinoid segment of the carotid artery. **E** : Superior view of the right LSC; The superior wall of the LSC has been removed. A partial hypophysectomy has been performed to expose the anterior and posterior coronary sinuses between the EL and the ML . **F** : posterior view of the right petroclival venous confluence. The CN VI reached the LSC by passing between the EL and the ML of the clivus, beneath the petrosphenoidal ligament of Grüber. A: artery; Ant: anterior; C: carotid; Clin: clinoidal; CN: cranial nerve; Diaph: diaphragm; Dist: distal; EL: endosteal layer; Lig: ligament; ML: meningeal layer; N: nerve; Pit: pituitary; Post: posterior; Prox,:proximal; Seg: segment.

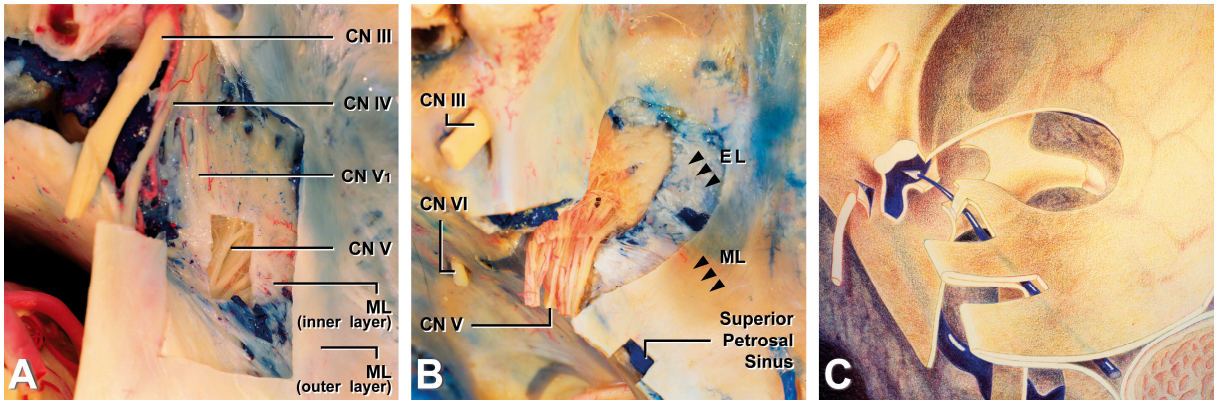

Figure 2 :

A : superior view of the left trigeminal cave. The superior layer which formed the roof of the trigeminal cave has been removed. The inferior layer of the roof has been partially dissected to expose the trigeminal nerve in the trigeminal fossa. **B** : The roof of the trigeminal fossa has been totally removed and the floor was exposed (EL) (arrows). The superior petrosal sinus emptied in the LSC, passing above the trigeminal nerve between the ML. **C** : illustration of the trigeminal fossa. The trigeminal nerve was lying beneath the middle cerebral fossa and its dural sheath formed by the ML of the middle cerebral fossa. The blue arrows correspond to the superior petrosal sinus. CN: cranial nerve; ML: meningeal layer.

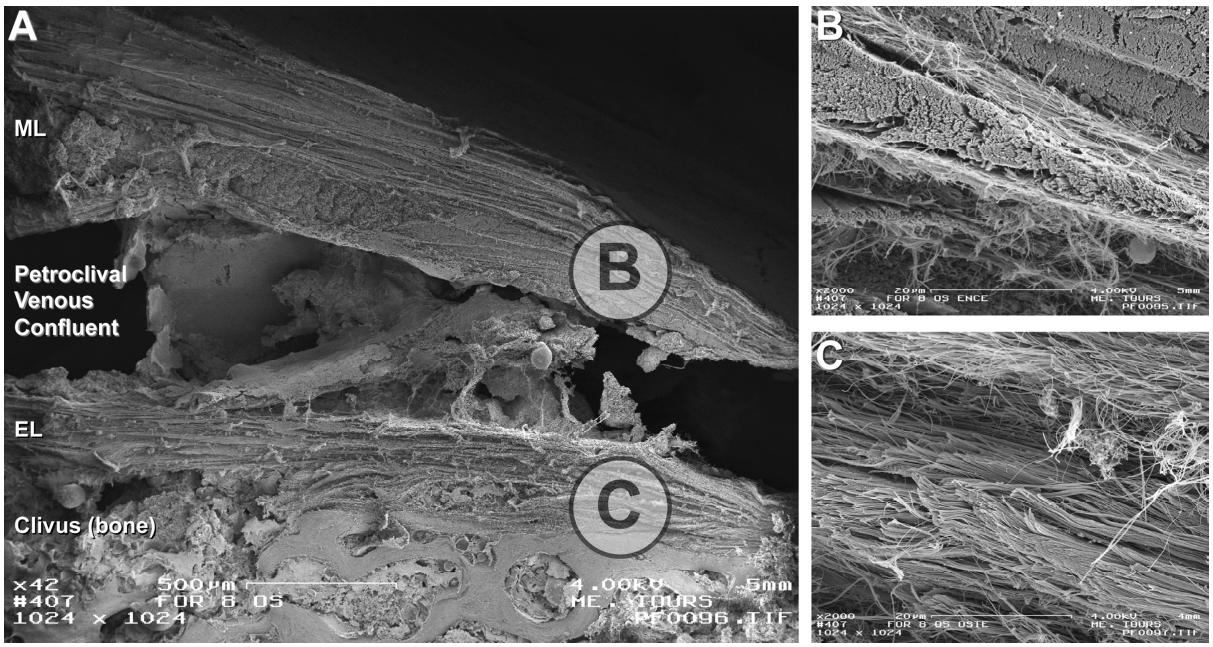

Figure 3 :

A : Sagittal view of the clivus; The clivus, EL, ML and Petroclival venous confluence have been removed *in toto* and observed with electron microscopy (x 42); The EL was attached to the clivus. The petroclival venous confluence was lying between the EL and the ML. **B** : photograph of a ML section (X2000): large collagenous bundles which are regularly aligned. **C** : photograph of an EL section (x2000): Fewer collagenous bundles were present. EL: endosteal layer; ML: meningeal layer.

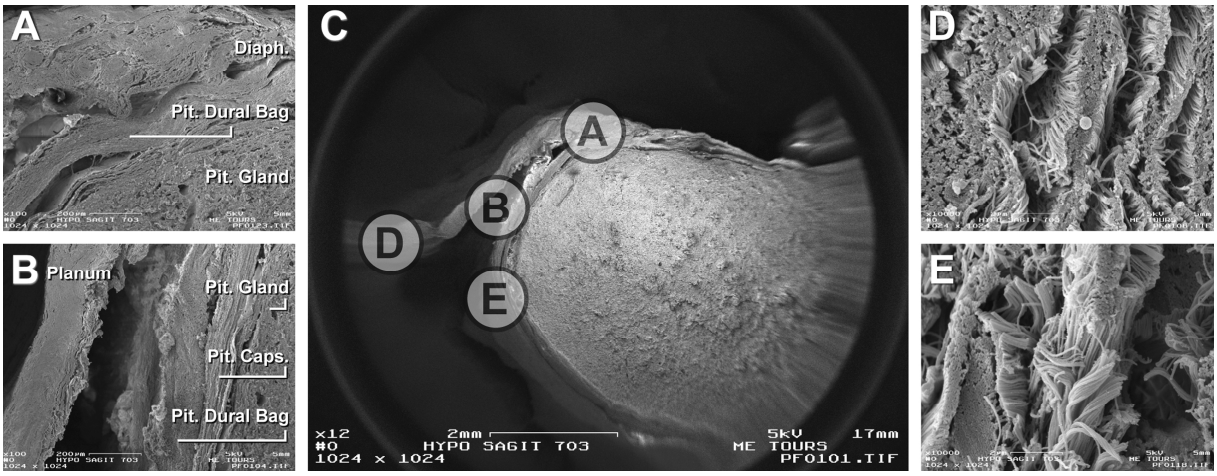

Figure 4 :

C : sagittal section of the dural bag which contained the pituitary gland with the ML of the anterior cranial fossa (X12). **A** : magnified view (X100) The ML which covered the anterior cranial fossa formed the diaphragm and the pituitary dural bag. **B** : magnified view (X 100) which exposed the pituitary gland and its capsule. **C** : the meningeal layer of the pituitary dural bag and the anterior cranial fossa. **D** : coronal section (X10000) of the ML of the anterior cranial fossa. **E** : coronal section (X10000) of the pituitary dural bag: dural bundles had similar collagenous fiber density and orientation. Caps: capsule; Diaph: diaphragm; Pit: pituitary.

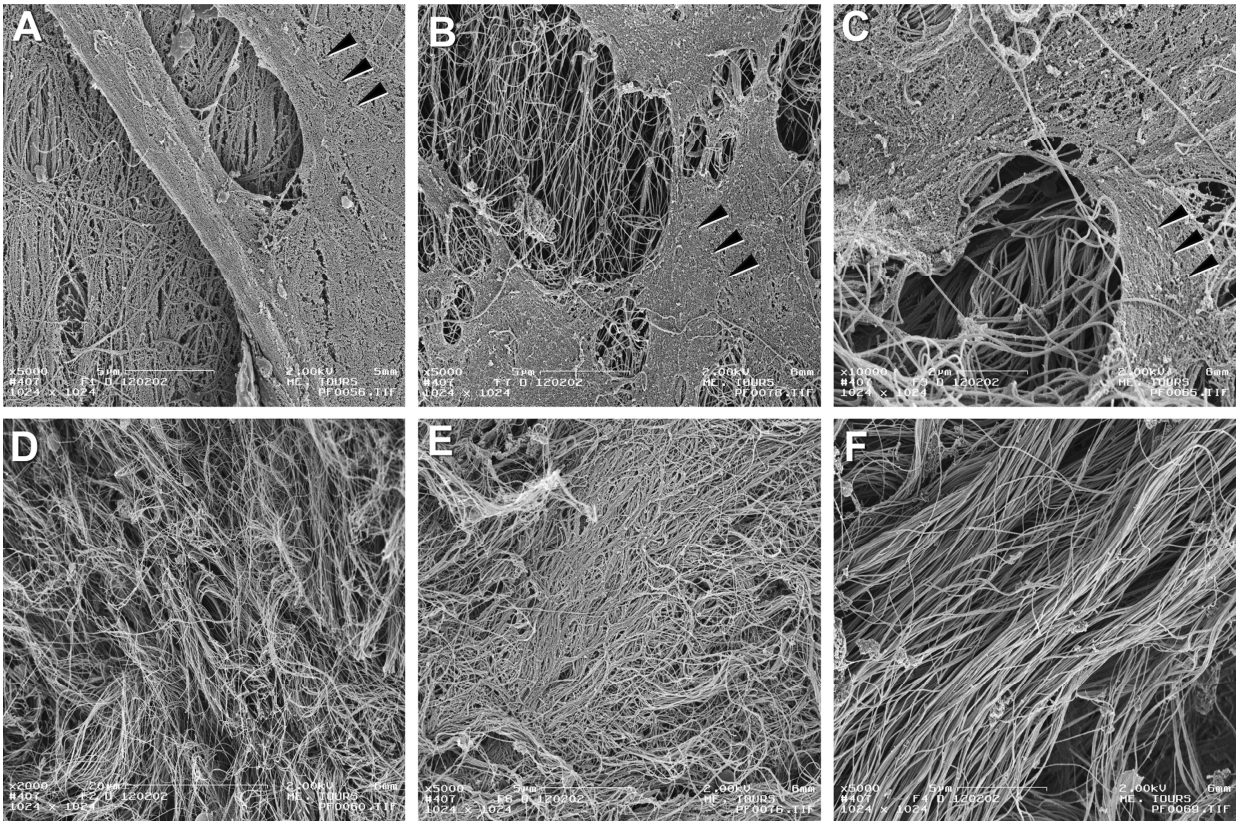

Figure 5 :

ML (ABC) and EL (DEF): superficial aspects on electron microscopy. **A** : ML of the clivus (X5000), **B** : optic dural sheath (X5000), **C** : lateral wall of the LSC (X10000), **D** : EL of the clivus (X2000), **E** : periorbita (X5000) and **F** : floor of the LSC (X5000). ABC had a similar aspect: a network of collagen fibres covered by amorphous material (arrows). DEF had extracellular collagen without this rough aspect. EL: endosteal layer; ML: meningeal layer.

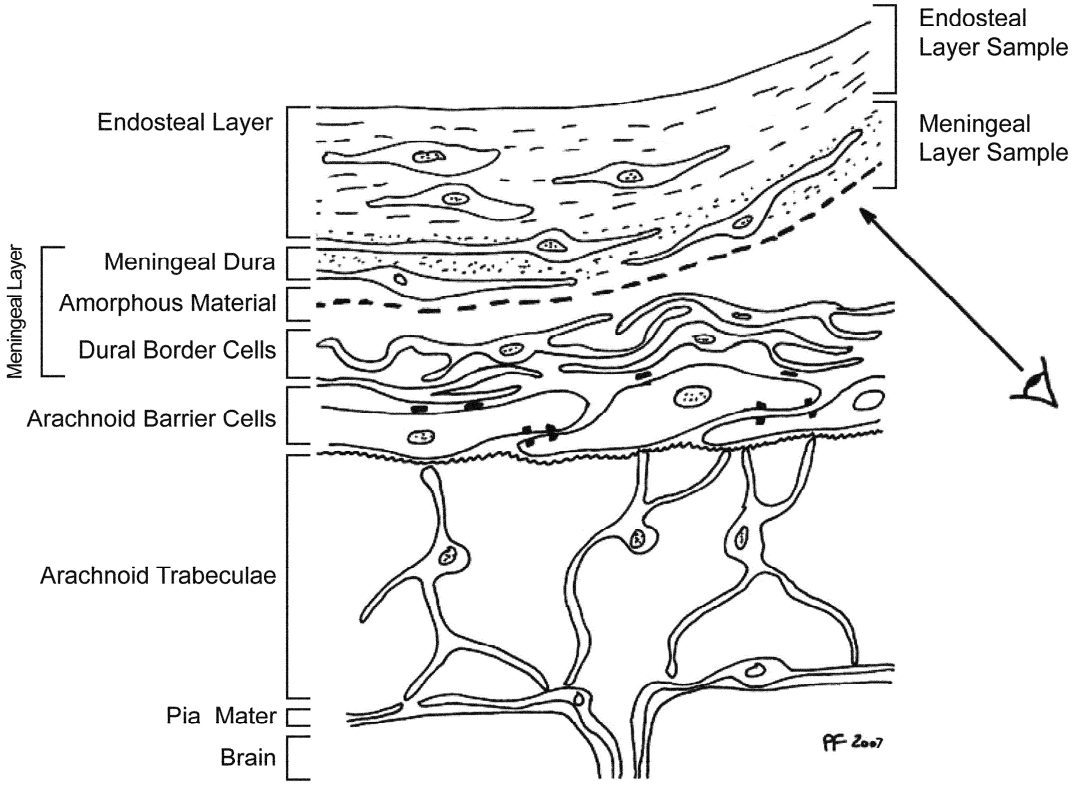

Figure 6 :

Semi-diagrammatic representation of the structure of the meninges inspirated by Hayne's work[12] on the subdural space. The endosteal layer of the dura mater was attached to the bone and contained large amounts of extracellular collagen. The meningeal layer of the dura mater was formed by dural border cells and the meningeal dura. The dural border cells were firmly attached to the arachnoid border cells and the extracellular collagen did not contain this cell layer. The arachnoid and dura were separated along the line of least resistance; this weak point may explain our results concerning the superficial aspect of the ML, which was based on electron microscopic data. (Fig. 5).

References

1. Al-Mefty O, Ayoubi S., Gaber E: Trigeminal schwannomas: removal of dumbbell-shaped tumors through the expanded Meckel cave and outcomes of cranial nerve function. **J Neurosurg 96:**453-463, 2002

2. Arnautovic KI, Al-Mefty O, Glenn Pait T, Krisht AF, Husain MM: The suboccipital cavernous sinus. **J Neurosurg 86:**252-262, 1997

3. Bonnet P: La loge caverneuse et les syndromes de la loge caverneuse. **Arch d'ophtalmologie 15:**332-357, 1955

4. Chi JG, Lee MH: Anatomical observations of the development of the pituitary capsule. **J.Neurosurg 52:**667-670, 1980

5. Ciric I: On the origin and nature of the pituitary gland capsule. **J Neurosurg 46:**596-600, 1977

6. Cottier JP, Destrieux C, Brunereau L, Bertrand P, Moreau L, Jan M, et al: Cavernous sinus invasion by pituitary adenoma: MR imaging. **Radiology 215:**463-469, 2000

7. Destrieux C, Velut S, Kakou MK, Lefrancq T, Arbeille B: A new concept in Dorello's canal microanatomy: the petroclival venous confluence. **J Neurosurg 87:** 67-72, 1997

8. Destrieux C, Kakou MK, Velut S, Lefrancq T, Jan M: Microanatomy of the hypophyseal fossa boundaries. **J Neurosurg 88:**743-752, 1998

9. Dietemann JL, Kehrli P, Maillot C, Diniz R, Reis M Jr, Neugroschl C, et al: Is there a dural wall between the cavernous sinus and the pituitary fossa? Anatomical and MRI findings. **Neuroradiology 40:** 627-630,1998

10. Dorello P: Considerazioni sopra la causa della paralisi transitoria dell' abducente nelle flogosi dell' orecchio medio. **Atti Clin Otorinolaringoiatrica Univ Roma 3:** 207-217, 1905

11. Frederickson RG: The subdural space interpreted as a cellular layer of meninges. **Anat Rec 230:** 38-51, 1991

12. Haines DE, Harkey HL, Al-Mefty O: The "subdural" space: a new look at an outdated concept. **Neurosurgery 32:**111-120, 1993

13. Hamann MC, Sacks MS, Malinin TI: Quantification of the collagen fibre architecture of human cranial dura mater. **J Anat 192:**99-106, 1998

14. Harris FS, Rhoton AL: Anatomy of the cavernous sinus. A microsurgical study. **J Neurosurg 45:**169-80, 1976

15. Inoue T, Rhoton AL Jr, Theele D, Barry ME: Surgical approaches to the cavernous sinus: a microsurgical study. **Neurosurgery 26:**903-932, 1990

16. Kawase T, van Loveren H, Keller JT, Tew JM: Meningeal architecture of the cavernous sinus: clinical and surgical implications. **Neurosurgery 39:**527-536, 1996

17. Kehrli P, Ali M, Reis M Jr, Maillot C, Dietemann JL, Dujovny M, et al: Anatomy and embryology of the lateral sellar compartment (cavernous sinus) medial wall. **Neurol Res 20:**585-92, 1998

18. Knosp E, Steiner E, Kitz K, Matula C: Pituitary adenomas with invasion of the cavernous sinus space: a magnetic resonance imaging classification compared with surgical findings. **Neurosurgery 33:**610-618, 1993

19. Krivosic I: Histoarchitecture of the cavernous sinus, in Dolenc VV (ed): **The cavernous sinus. A Multidisciplinary Approach to Vascular and Tumorous lesions.** Vienna: Springer-Verlag, 1987, pp 117-129

20. McDowell EM, Trump BJ: Histological fixatives suitable for diagnostic light and electron microscopy. **Arch Pathol Lab Med 100:** 405-414, 1976

21. McLone D: The subarachnoid space : a review. **Child's brain 6:**113-130, 1980

22. Nabeshima S, Reese TS, Landis DM, Brightman MW: Junctions in the meninges and marginal glia. **J Comp Neurol 164:**127-170, 1975

23. Parkinson D: A surgical approach to the cavernous portion of the carotid artery. Anatomical studies and case report. **J Neurosurg 23:**474-483, 1965

24. Parkinson D: Extradural neural axis compartment. **J Neurosurg 92:**585-588, 2000a

25. Parkinson D: History of the extradural neural axis compartment. **Surg Neurol 54:**422-431, 2000b

26. Patouillard P, Vanneuville G: [The walls of the cavernous sinus]. **Neurochirurgie 18:**551-560, 1972

27. Poirier P: **Traité d'Anatomie Humaine.** Paris: Masson, 1894,Vol 3, Fasc 1, pp 97-104

28. Schachenmayr W, Friede RL: The origin of subdural neomembranes. I. Fine structure of the dura-arachnoid interface in man. **Am J Pathol 92:**53-68, 1978

29. Taptas JN: La loge du sinus caverneux sa constitution et les rapports des éléments vasculaires et nerveux qui la traversent. **Sem Hop 40:**1719-1722, 1949

30. Taptas JN: the so-called cavernous sinus: a review of the controversy and its implications for neurosurgeons. **Neurosurgery 11:**712-717, 1985

31. Thapar K, Kovacs K, Scheithauer BW, Stefaneanu L, Horvath E, Pernicone PJ, et al: Proliferative activity and invasiveness among pituitary adenomas and carcinomas: An analysis using the MIB-1 antibody. **Neurosurgery 38:**99-107, 1996

32. Umansky F, Nathan H: The lateral wall of the cavernous sinus. With special reference to the nerves related to it. **J Neurosurg 56:**228-234, 1982

33. Vesalius A: *Andreae Vesalii Bruxellensis, Scholae Medicorum Pataminae Professoris: De humani corporis fabrica libri septem.* Basilae, ex officina Ioannis Oporini, 1543. http: //www.cesr.univ-tours.fr

34. Weninger WJ, Streicher J, Muller GB: Anatomical compartments of the parasellar region: adipose tissue bodies represent intracranial continuations of extracranial spaces. **J Anat 191:**269-275, 1997

35. Wolfsberger S, Ba-Ssalamah A, Pinker K, Mlynárik V, Czech T, Knosp E, et al: Application of three-tesla magnetic resonance imaging for diagnosis and surgery of sellar lesions. **J Neurosurg 100:**278-286, 2004

36. Yasuda A, Campero A, Martins C, Rhoton AL Jr, Ribas GC: The medial wall of the cavernous sinus: microsurgical anatomy. **Neurosurgery 55:**179-189, 2004

37. Yokoyama S, Hirano H, Moroki K, Goto M, Imamura S, Kuratsu JI: Are nonfunctioning pituitary adenomas extending into.the cavernous sinus aggressive and/or invasive? **Neurosurgery 49:**857-863, 2001

38. Youssef S, Kim EY, Aziz KM, Hemida S, Keller JT, van Loveren HR: The subtemporal interdural approach to dumbbell-shaped trigeminal schwannomas: cadaveric prosection. **Neurosurgery 59:**270-278, 2006

.

Acknowledgments

We are indebted to Donald SCHWARTZ, M.D., from Tours for his help in proofreading this paper. We also thank Gerald DELUERMOZ, Jean Paul DA SILVA (Université François Rabelais de Tours, Laboratoire d'Anatomie), Daniel BOURRY (Université François Rabelais de Tours, Service d'Iconographie) and Claude LEBOS (Université François Rabelais de Tours, Département de Microscopie Electronique) for their technical help. The neoprene latex (#671) was a gift from Laboratoires Safic-Alcan, Puteaux, France

This study was supported by the Association du Don du Corps, Université François Rabelais de Tours, Laboratoire d'Anatomie.

Nous avons utilisé ce même principe de travail pour étudier la gaine durale du nerf optique. Il nous a paru essentiel de reprendre l'anatomie descriptive de cette gaine et de la compléter par une approche en microscopie électronique, illustrée de quelques planches d'IRM montrant les rapports des espaces sous-arachnoïdiens avec la gaine durale du nerf optique. L'espace clinoïdien antérieur est une région mise à nu lorsqu'on réalise une clinoïdectomie antérieure : les rapports méningés à ce niveau sont particulièrement complexes puisque la gaine durale du nerf optique est en contact avec les anneaux carotidiens et participe à la constitution du toit de la loge caverneuse avec la membrane carotido-oculomotrice.

La gaine durale du nerf optique est la plus solide, la plus longue aussi accompagnant le nerf optique du ligament falciforme au globe oculaire. A ce niveau, elle devient la sclère et participe par son ultrastructure collagénique à la rigidité du globe oculaire. La gaine durale du nerf optique représente l'extrémité rostrale du concept inter-périostéo-dural. Elle est séparée du périorbite qui représente le feuillet ostéo-périosté par de la graisse particulièrement importante dont la finalité est de faciliter les mouvements de glissements des muscles oculaires. À partir de cette anatomie descriptive, il est utile de détailler quelques techniques chirurgicales que nous utilisons pour traiter des tumeurs de cette région. Les techniques de clinoïdectomies par voie extra-durale, des abords de l'orbite en sont des exemples mais comprendre l'anatomie de la gaine durale du nerf optique, c'est aussi mieux comprendre certaines pathologies comme l'hypertension intra-crânienne bénigne. Ce travail a fait l'objet d'une publication dans la revue **Advances and Technical Standards in Neurosurgery**. Cette publication est acceptée, elle est destinée à un public de jeunes neurochirurgiens et permet d'intégrer cette anatomie difficile au sein d'un concept moderne de la dure-mère. Elle permet aussi d'illustrer ces propos descriptifs par des applications cliniques simples.

The dural sheath of the optic nerve: descriptive anatomy and surgical applications

Patrick FRANCOIS [1,2], Emmanuel LESCANNE [3], Stéphane VELUT [1,2]

1 Université François Rabelais de Tours, laboratoire d'anatomie, Tours, France
2 CHRU de Tours, service de Neurochirurgie, Tours, France
3 CHRU de Tours, service d'Oto-Rhino-Laryngologie, Tours, France

Address reprint requests to :

Patrick François, M.D.

CHRU de Tours

Service de neurochirurgie

10 Boulevard Tonnellé

F-37044 Tours, cedex 9

France.

Email : francois@med.univ-tours.fr

Fax : (33) 02 47 47 80 96

Phone : (33) 02 47 47 37 16

Abstract :

The aim of this work was to clarify the descriptive anatomy of the optic dural sheath using microanatomical dissections on cadavers. The orbit is the rostral part of the extradural neural axis compartment; the optic dural sheath forms the central portion of the orbit.

In order to describe this specific anatomy, we carefully dissected 5 cadaveric heads (10 orbits) up to the meningeal structure of the orbit and its contents. 1 cadaveric head was reserved for electron microscopy to add to our knowledge of the collagen structure of the optic dural sheath.

In this chapter, we describe the anatomy of the interperiostal-dural concept and the anatomy of the orbit. The optic dural sheath contains three portions: the intracranial, the intracanalicular and the intraorbital segment. Each one has specific anatomic relations which result in particular surgical considerations.

Key Words: Optic nerve; dural sheath; anatomy; skull base surgery

Introduction :

The dural sheath of the optic nerve is a structure which has received little attention in the literature. Nevertheless, it illustrates a broader idea of the dura mater: the interperiostodural concept. This sheath has the particularity of being the longest of the transbasal sheaths. It courses along with the optic nerve from its foramen to the orbit. At this point, it reinforces the sclera and provides the optic globe with its characteristic biomechanical properties. In this chapter we will successively discuss the embryology and the principles of the interperiostodural concept followed by a descriptive anatomy of this dural sheath and try to clarify its relations to nearby structures and the surgical implications at the level of each of its three segments: intracranial, intracanalicular and intraorbital.

Embryology

The optic vesicle begins to form as an evagination on the diencephalic neural fold on day 22. The stem of the optic vesicle narrows to form the optic stalk. The nerve fibers that emerge from the retinal ganglion cells in the sixth week travel through the optic stalk to reach the brain. The optic stalk is transformed into the optic nerve. As the optic vesicle forms, it is surrounded by a sheath of mesenchyme which differentiates to form the two coverings of the optic globe: an inner, pigmented, vascular layer called the choroid (homologous in origin with the pia mater and arachnoid membranes) and an outer, fibrous layer called the sclera (homologous with the dura mater). This latter tissue gives rise to the optic dural sheath whereas the choroid gives rise to the subarachnoid space between the optic nerve and its dural sheath (fig.1). The subarachnoid space extends through the bony optic canal and along the optic nerve to the globe (Fig.4). However, the extent of communication in the optic canal showed wide variation from one specimen to another. This subarachnoid space is larger distally (near the globe) than proximally (region of the optic canal). Elevation of intracranial cerebrospinal fluid pressure is transmitted to the subarachnoid space surrounding the optic nerve sheath and thence into the optic nerve parenchyma leading to stasis of normal axoplasmic flow resulting in optic disk swelling. This

mechanical theory explains pathogenesis of disk swelling in patients with elevated intracranial pressure.

The interperiosteodural concept

The dura mater of the brain in comprised by two layers: an osteoperiostal layer which adheres to the bone and a thicker, encephalic layer which remains in contact to the arachnoid. These two layers adhere to one another at the level of the cranial vault but are separated at the dural sinuses and the interperiosteodural spaces represented by the orbits, the cavernous spaces and the “epidural” rachidial space. These interperiosteodural spaces are filled with adipose tissue and veins. The adipose tissue serves to improve movement between the two sheets. The fatty tissue is less developed at the level of the cavernous space (7, 19). Apart from the area of the sinuses, the venous lacunae are placed between these sheets and are more developed near the clivus where they form the petroclival venous confluent (3). The internal carotid artery and the abducens nerve pass through this interperiosteodural space (3, 8).

The interperiosteodural concept has been especially studied at the level of the cavernous spaces. Ridley, in 1695, was the first to describe the parasellar region as a venous space surrounding the internal carotid artery (14). In 1732, Winslow coined the term “cavernous sinus” for this region by analogy with the cavernous body of the penis since it contains fibrous trabeculae within its confines (20). In 1949, first Taptas followed by Bonnet in 1955 described this sinus as a space located between the two layers of the dura mater (16, 1). This space has been the object of innumerous controversies. Finally, the notion of the cavernous space as being a space located between an osteoperiostal layer and an encephalic layer has since been extended to include the orbit and the spine inasmuch as the interperiosteodural concept has become an accepted anatomical concept extending from the coccyx to the sclera (9, 10, 11).

In the cavernous space, the lateral wall is thus constituted by a layer of encephalic dura mater which is continuous with the encephalic layer covering the middle cerebral fossa. This last-mentioned is doubled by a second plane formed by the juxtaposition of the dural sheathes of the cranial nerves coursing along the lateral wall of the cavernous space (4, 12, 18). Consequently, these dural sheathes

accompanying the cranial nerves up to the superior orbital fissure, which they cross in order to join the orbit, participate in forming the thickness of the lateral wall of the space. The medial wall of the cavernous space is formed by the hypophyseal dural sac constituted by the encephalic dura mater (2) dorsally and the periostium which covers the sphenoid ventrally. Between these two layers lie the coronary sinuses which represent intercavernous anastomoses just like the venous space of the clivus space anastomoses with the petroclival venous confluents. At the junction of the cavernous space and the orbit, the osteoperiostal layer continues through the periorbit while the encephalic layer continues through the dural sheath of the optic nerve. Thus, anatomic elements of the orbit annexed to the optic tracts are located between these two structures. The dural sheath of the optic nerve forms a fibrous sleeve which is in fact an invagination of the encephalic layer of the anterior base of the skull at the optic porus.

The orbit is therefore an interperiosteodural space corresponding to the rostral prolongation of the cavernous space. This space contains the vascular and nervous elements of the orbital cone surrounded by intra and extra-conic fatty islets. The dural sheath of the optic nerve is positioned at its center.

Described in this manner, the dural sheath of the optic nerve originates at the level of the optic canal and accompanies the optic nerve to the sclera. It is constituted by a close-knit meshwork of collagen fibers (fig. 1). Its collagen architecture provides indisputable mechanical properties since a 1 mm diameter collagen fiber is estimated to have a resistance of 10 kg. The dural sheath of the optic nerve includes three different segments which need to be described: the very short intracranial segment, the intracanalicular segment in the optic canal and an intraorbital segment which extends to the sclera.

Intracranial segment

This segment is very short and is essentially constituted by the invagination of the encephalic layer of the sphenoid planum at the level of the optic canal. This meningeal invagination does not adhere perfectly to the bone and gives rise to the falciform ligament. It can be a few millimeters in length. This ligament normally protects the dorsal surface of the optic nerve although, when an infraoptic tumor is present, it may shear it. Indeed, meningiomas of the tubercule of the sella turcica or

of the sellar diaphragm can lift up the visual pathways and as a result, the ligament can leave its imprint on their dorsal surface. This fact may explain some preoperative altitudinal visual defects. Accordingly, the surgical approach to these tumors requires opening this falciform ligament before mobilization of the visual pathways.

Intracanalicular segment

At this level, the relations of the dural sheath are mainly with bony structures and the meninges.

Relations with bony structures

The dural sheath of the optic nerve exits the base of the skull through the optic canal which courses obliquely in a lateral and ventral direction. It is located at the junction of the lesser wing and the body of the sphenoid (fig. 2). It comes into close contact with the anterior clinoid process which forms its lateral border. The anterior clinoid process is attached to the body of the sphenoid by two bony bridges which form the floor and the roof of the optic canal (15). The roof of the canal is anterior to the floor; this explains why the plane of the optic porus is not coronal. The optic canal has a truncal form and is wider in the back (elliptical shape) than in the front (circular shape). The optic porus is separated from the superior orbital fissure by a bony bridge called the “optic strut”. This structure is an important surgical landmark when accessing the extra-dural portion of the anterior clinoid process. The “optic strut” joins the lesser wing of the sphenoid to the lateral wall of the sphenoid sinus. During the surgical treatment of spheno-orbital meningiomas, loss of vision in the patient requires that drilling be extended to the dural sheath of the optic nerve. The optic strut should constitute the medial limit of the drilling process; if drilling is continued further medially the sphenoid sinus will be opened, exposing the patient to postoperative rhinorrhea and possible infectious complications. The floor of the optic canal forms a relief in the sphenoid sinus which is an important landmark during endoscopic surgery of the pituitary gland. At this level, it is located above the anterior bend of the intracavernous carotid, lateral to the floor of the sella turcica. The bone can be very thin or even absent and when that is the case, the dural sheath of the optic nerve is in direct contact with the mucosa of the sphenoid sinus (fig. 3A).

Meningeal Relations

The meningeal relations of the dural sheath of the optic nerve are complex in the region of the sella turcica. In order to clearly understand them, the anterior clinoid process has to be drilled in order to expose the anterior clinoid space. The dura mater covering the ventral surface of the clinoid process forms a “carotidoculomotor membrane” strung between the internal carotid artery medially and the dural sheath of the oculomotor nerve. This membrane forms the meningeal roof of the cavernous space (fig. 2C). The carotidoculomotor membrane is constituted by encephalic dura mater; medially it forms the proximal and distal carotid rings (fig. 2D). The clinoid segment of the internal carotid is comprised between these two rings. The internal carotid forms its cavernous segments ventrally to the proximal carotid ring. Dorsally to the distal ring, it penetrates into the subarachnoid spaces. At this point, the dural sheath of the optic nerve is in contact with the distal carotid ring (fig. 2D). The ophthalmic artery constitutes the first branch of the internal carotid artery, arising medial to the anterior clinoid process. It then joins the orbit after traversing the optic canal.

During the surgical treatment of carotid and ophthalmic aneurysms, the anterior clinoid process should be drilled in order to clearly expose the origin of the ophthalmic artery and allow the aneurysm to be isolated with a clip. Hashimoto (5) insisted on the fact that a preoperative 3D angioscan can help the surgeon determine the exact location of the aneurysm’s collar in relation to the optic strut (a radiological landmark) and thereby improve subsequent therapeutic strategy. When the aneurismal collar is dorsal to the optic strut, the aneurysm should most often be treated surgically. However, when the collar is ventral to the optic strut, the aneurysm is intracavernous and should be treated with an endovascular technique.

Yang (21) reviewed the principles involved in extradural anterior clinoidectomy when techniques for the post-traumatic decompression of the optic nerve are employed. He underlined the fact that the clinoid segment of the internal carotid is only separated from the medial border of the anterior clinoid process by a thin meningeal sheet: the carotid collar. This meningeal structure is stretched between the carotid rings. The proximal ring is often incomplete while the distal ring is tightly packed. This fact explains why venous blood coming from the cavernous spaces can surround the clinoid segment of the internal carotid. A clinoidectomy

using the extradural approach which is indispensable for gaining access to the dural sheath of the optic nerve, can prove to be difficult especially when the sheath is prominent caudally. It should be carefully drilled so as to avoid injury to the internal carotid. After this preparatory bony procedure, the dural sheath of the optic nerve is exposed then incised along the optic nerve from the falciform ligament to the anular tendon (anulus of Zinn) between the insertion of the lateral and superior rectus muscles.

Intraorbital segment

In its orbital segment, the relations of the dural sheath of the optic nerve are essentially with the vascular and nervous elements going to the orbit. At the exit of the optic canal, the meninges of the sheath of the optic nerve become particularly dense (fig. 3B). At this level, it helps form the anular tendon ring where the muscles providing mobility to the ocular globe and its annexes (eyelid) insert. The anular tendon forms the apex of the orbital cone through which course the dural sheath of the optic nerve dorsally in addition to the abducens nerve, the nasociliary nerve, the superior and inferior branches of the oculomotor nerve and the ophthalmic artery. The dural sheath of the optic nerve is an essential surgical landmark beyond the anular tendon since it represents the central element in the orbital cone formed by the rectus, levator and oblique muscles. It is surrounded by adipose tissue which facilitates eye movements in the three spatial planes.

The ophthalmic artery arises at the medial border of the internal carotid, in general beyond the distal carotid ring, but sometimes at the level of the clinoid segment between the two carotid rings or at the cavernous sinus (8 % of the cases) (13, 15), above the proximal carotid ring. When this is the case, it joins the orbit through the superior orbital fissure. The ophthalmic artery accompanies the optic nerve in its sheath, traveling along its inferomedial border (fig.3D). Beyond the optic canal, it travels obliquely through the sheath of the optic nerve and joins the orbital apex lateral to the optic nerve. Occasionally, it gives off a recurrent branch in the optic canal which takes part in the vascularization of the intracanalicular segment of the optic nerve (17). In 85 % of the cases, the ophthalmic artery crosses the dural sheath of the optic nerve dorsally where it lies between the medial rectus and superior oblique muscles before giving rise to the anterior and posterior ethmoid

arteries. The ophthalmic artery also gives rise to the lacrymal, the ciliary, the supraorbital, the medial palpebral, the infratrochlear and the dorsal nasal arteries. The central retinal artery is the smallest of its branches considering its diameter but the most important according to its function since it is a terminal branch which provides vascularization to the macula. The central retinal artery pierces the dural sheath of the optic nerve at the junction between the anterior 1/3 and median 1/3 about twenty millimeters from the optic canal following a short, serpiginous trajectory. There it lies in the optic nerve up to the globe and vascularizes the retina. The central retinal artery can present anatomical variations: origin by a common trunk along with the posterior ciliary or muscular arteries, a proximal origin with a long intraorbital trajectory before penetrating the dural sheath of the optic nerve, or finally, with a distal origin and a very short intraorbital trajectory. The intraorbital portion of the optic nerve derives its blood supply from a rich anastomotic vascular network located in the pia mater which is supplied by the ciliary arteries. Optic nerve meningiomas are derived from arachnoidal cap cells and may grow in a subdural, extradural or combined location. It may focally enlarge or may extend axially along the nerve to the intracranial compartment. Optic sheath meningioma in the posterior orbit are virtually impossible to resect completely without resulting in blindness. Optic neuropathy after surgical treatment may be due to inadvertent retraction, vascular compromise or heat transmission from bipolar coagulation energy or drilling.

In summary, five different elements cross the orbital segment of the dural sheath of the optic nerve dorsally:

- The trochlear nerve in back which exits the cavernous space through the superior orbital fissure. It has an extra-conic trajectory under the periorbit and joins to the superior oblique muscle which it innervates (fig. 3B).
- The frontal nerve, the dorsal dividing branch of the ophthalmic nerve, which arises at the superior orbital fissure outside the common tendon ring and lies under the periorbit in front of the trochlear nerve. It courses above the levator muscle and gives off the supratrochlear and supraorbital nerves (fig. 3C).
- The nasociliary nerve is the second dividing branch of the ophthalmic nerve. It also arises at the superior orbital fissure ventrally to the frontal nerve. It travels in the orbital cone and joins the anteromedial compartment

of the orbit. It gives off the long ciliary nerves and distributes sympathetic fibers to the dilator muscle of the pupil. These fibers course around the intracavernous carotid and join the ophthalmic nerve at the cavernous space.

- The ophthalmic artery crosses over the optic nerve's dural sheath. It sometimes crosses the dural sheath of the optic nerve ventrally before reaching the anteromedial compartment of the orbit.
- The superior ophthalmic vein receives anastomoses from the facial and supraorbital veins. It travels under the superior rectus muscle and crosses over the dural sheath of the optic nerve before taking up a position along the sheath's lateral border. It empties into the cavernous space by exiting the orbit through the superior orbital fissure, outside the anular tendon.

Orbital lesions can be approached by the transcranial, transmandibular, transnasal, transethmoid, or finally, the lateral or transconjunctival orbital route (13). The choice of surgical approach depends on the lesion's localization, size, and characteristics as well as the operator's experience and preference. Most of the time, two approaches are available to neurosurgeons: the transcranial and the lateral approach. The transcranial provides access to the orbital apex through its dorsal wall and to the compartment located medial to the dural sheath of the optic nerve when the space between the levator muscles of the eyelid and the superior oblique are open. In order to treat lesions which have appeared in front of the superior orbital fissure or along the lateral border of the dural sheath of the optic nerve, the surgeon must open the space located between the superior and the lateral rectus muscles (6). These upper approaches require a craniotomy and drilling of the roof of the orbit. The trochlear and frontal nerves are particularly exposed to injury due to their extraconic location, under the periorbit. In contrast, the central retinal artery is protected by the dural sheath of the optic nerve. In lateral approaches to the orbit, drilling removes the lateral wall of the orbit and provides access to the inferolateral quadrant of the orbit by passing under the lateral rectus muscle. This approach minimizes the risks of injury to the trochlear and frontal nerves but opens the door to injuring the central retinal artery or the short ciliary nerves.

Conclusion :

The optic dural sheath is the longest dural sheath. It describes an intracranial, intracanalicular and intraorbital segments with specific surgical implications. The optic dural sheath forms the encephalic layer of the orbital compartment of the extra dural axis compartment which is an anatomic concept applied from the coccyx to the orbit.

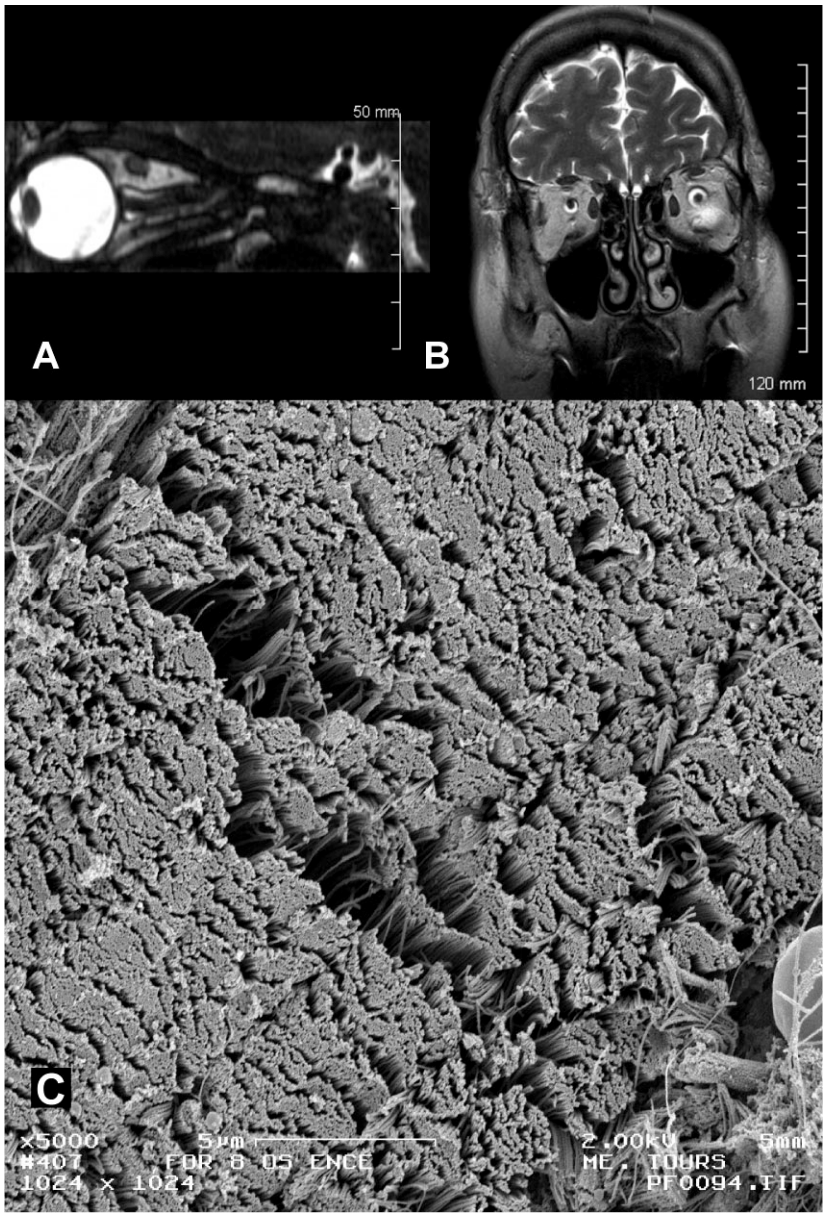

Fig. 1. Sagittal T2-weighted (**A**) and coronal T2-weighted (**B**) MRI scans of the orbit. The cerebrospinal fluid is contained in the subarachnoid space surrounding the optic nerve. This subarachnoid space extends through the bony optic canal and along the optic nerve to the

globe. **C** : An electron micrographic coronal section of the dural sheath of the optic nerve (X 5000). The dura mater is composed of fibroblasts and extensive quantities of extracellular collagen.

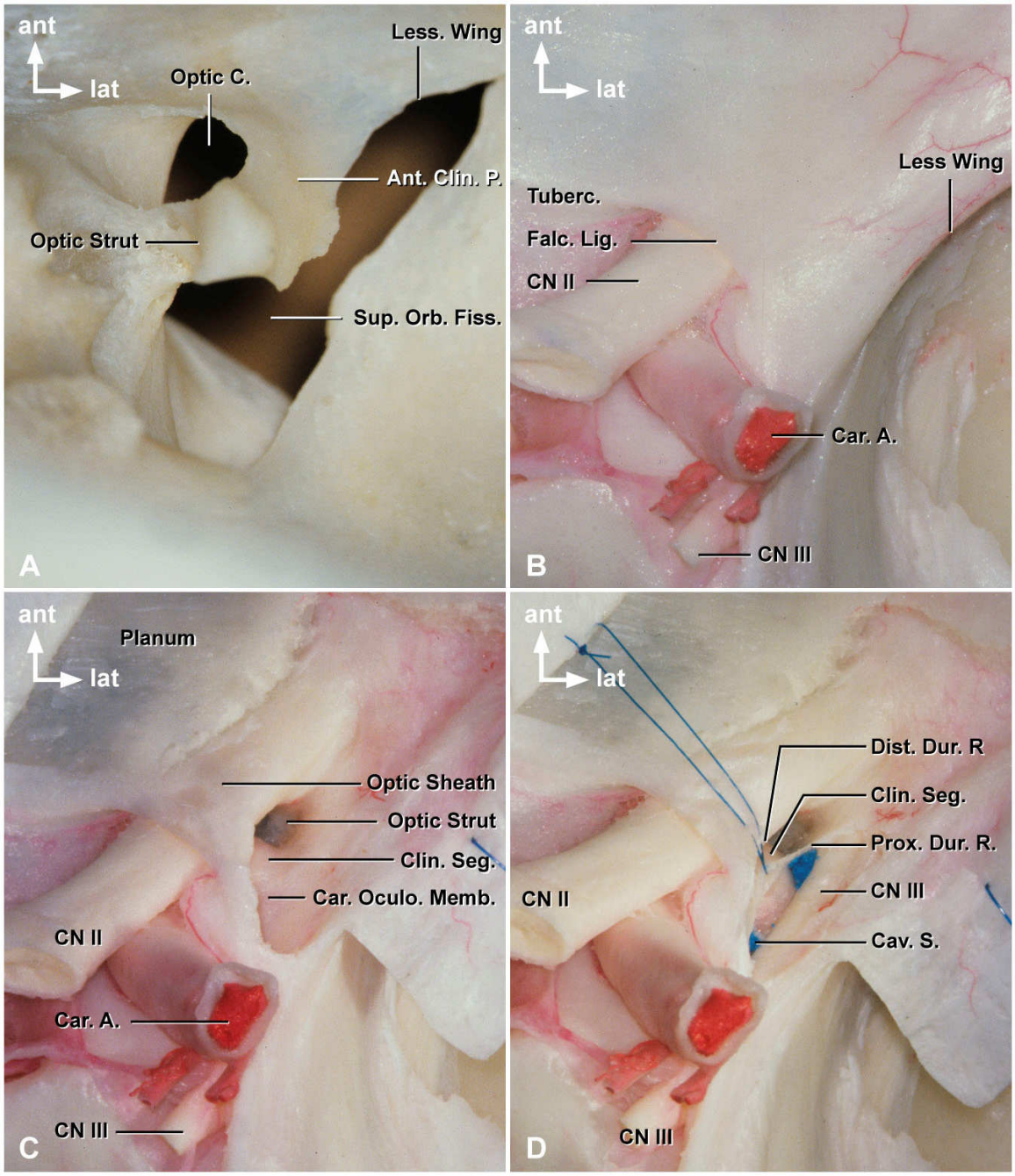

Fig. 2. A : Superior view of the right optic canal. The dura mater has been removed. The optic canal, which provides passage for the optic nerve and the ophthalmic artery, opens into the orbital apex. It is separated from the superior orbital fissure by the optic strut which forms the floor of the optic canal. The optic strut and the roof of the optic canal constitute the anterior and posterior roots of the lesser wing of the sphenoid bone. **B** : Superior view of the roof of the cavernous sinus without dissection. **C** : The anterior clinoid process and the optic strut have been drilled to expose the anterior clinoid space. The dura that lines the lower margin of the anterior clinoid process and extends medially above the oculomotor nerve to surround the internal carotid artery and form the proximal dural ring is referred to as the

carotidoculomotor membrane. The clinoid segment of the carotid artery is located between the proximal and distal dural rings. Above the distal dural ring, the carotid artery lies in the subarachnoid space and below it the cavernous sinus can be seen. **D** : The proximal dural ring around the carotid artery has been opened to expose the oculomotor nerve in the lateral wall of the cavernous sinus (blue latex).

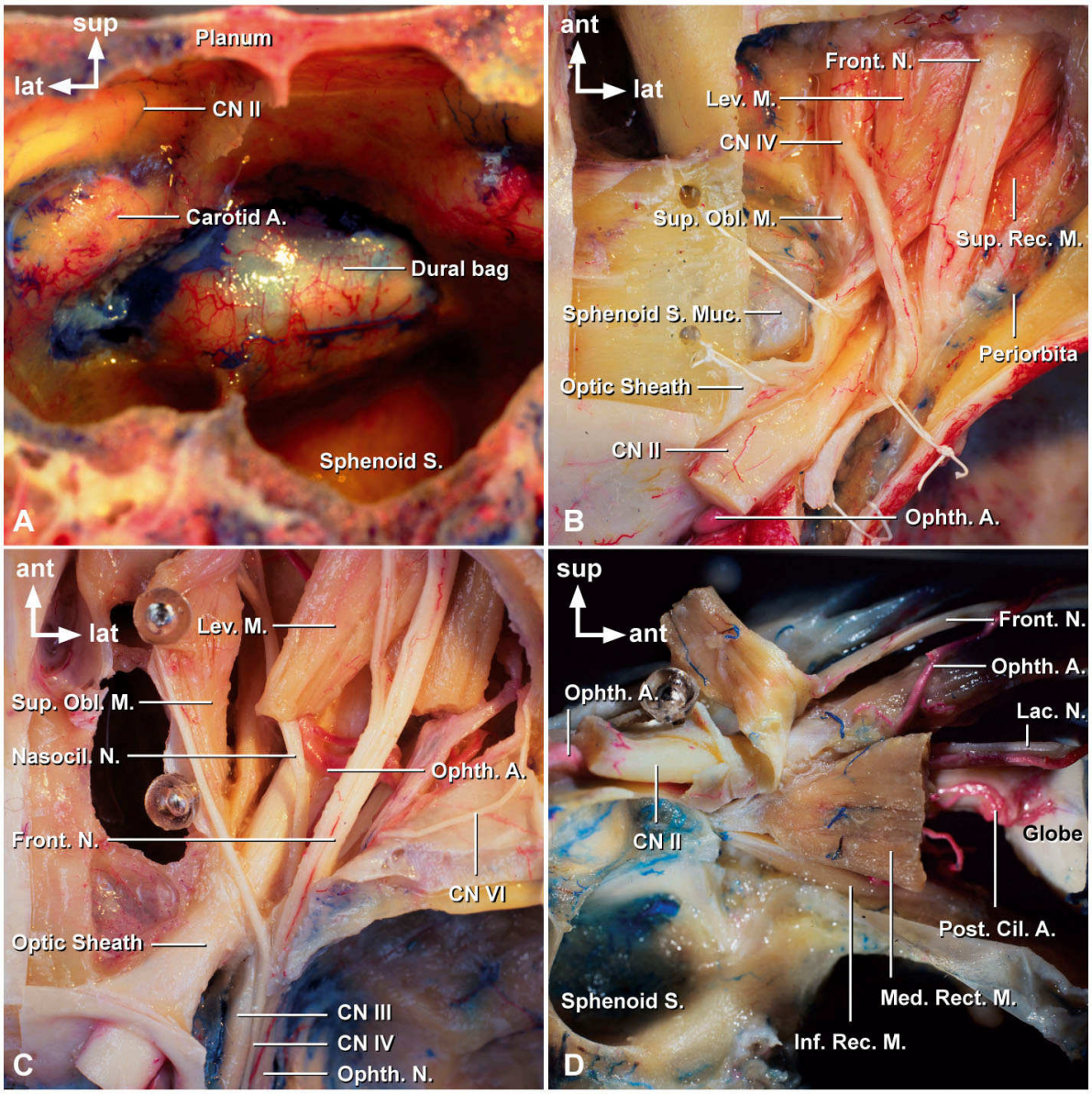

Fig. 3. A : Coronal section of the sphenoid sinus. The bone has been drilled to expose the hypophyseal dural sac containing the hypophysis. The optic nerve lies above the anterior loop of the carotid artery in the cavernous sinus. **B** : Superior view of the right optic canal. The bone has been drilled and the dural sheath of the optic nerve has been opened to expose the optic nerve. The trochlear and frontal nerves cross the optic nerve and lie outside muscles just below the periorbit. The ophthalmic artery arises from the intracranial internal carotid artery and extends along the inferolateral aspect of the optic sheath. **C** : Superior view of the right orbit. The frontal nerve and the levator and superior rectus muscles have been divided and reflected to expose the ophthalmic artery and the nasociliary nerve as they pass above the optic nerve. The abducens nerve courses on the medial side of the ophthalmic nerve in the cavernous sinus, but it passes below the ophthalmic nerve in the superior orbital fissure to enter the medial surface of the lateral rectus muscle. **D** : Medial view of the left orbit. The levator and medial rectus muscles have been sectioned to expose the distal dural sheath of the optic nerve near the globe. After passing above the optic nerve

(85 % of the cases), the ophthalmic artery courses between the superior oblique and the medial rectus muscles where it gives rise to the anterior and posterior ethmoidal arteries, the posterior ciliary artery and the meningeal branch for the dural sheath of the optic nerve.

References :

1. Bonnet P (1955) La loge caverneuse et les syndromes de la loge caverneuse . Arch d'ophtalmologie 15: 332-357

2. Destrieux C, Kakou MK, Velut S, Lefrancq T, Jan M (1998) Microanatomy of the hypophyseal fossa boundaries. J Neurosurg 88: 743-752

3. Destrieux C, Velut S, Kakou MK, Lefrancq T, Arbeille B, Santini JJ (1997) A new concept in Dorello's canal microanatomy: the petroclival venous confluence. J Neurosurg 87: 67-72

4. Harris FS, Rhoton AL (1976) Anatomy of the cavernous sinus. A microsurgical study. J Neurosurg 45: 169-180

5. Hashimoto K, Nozaki K, Hashimoto N (2006) Optic strut as a radiographic landmark in evaluating neck location of a paraclinoid aneurysm. Neurosurg 59: 880-887

6. Morard M, Tcherekayev V, de Tribolet N (1994) The superior orbital fissure: a microanatomical study. Neurosurg 35:1087-1093

7. Mukherji SK, Tart RP, Fitzsimmons J, Belden C, McGorray S, Guy J (1994) Fat-suppressed MR of the orbit and cavernous sinus: comparison of fast spin-echo and conventional spin-echo. AJNR Am J Neuroradiol 15: 1707-1714

8. Parkinson D (1965) A surgical approach to the cavernous portion of the carotid artery. Anatomical studies and case report. J Neurosurg 23: 474-483

9. Parkinson D (1991) Human spinal arachnoid septa, trabeculae, and "rogue strands". Am J Anat 1992: 498-509

10. Parkinson D (2000a) Extradural neural axis compartment. J Neurosurg 92: 585-588

11. Parkinson D (2000b) History of the extradural neural axis compartment. Surg Neurol 54: 422-431

12. Patouillard P, Vanneuville G (1972) The walls of the cavernous sinus. Neurochirurgie 18: 551-560

13. Rhoton AL, Natori Y (1996) Surgical approaches. In: Rhoton Al, Natori Y (eds) The orbit and sellar region: microsurgical anatomy and operative approaches. Thieme Medical publishers, New York

14. Ridley (1695) The anatomy of the brain. Vol 39. London

15. Seoane JR, Rhoton AL, de Oliveira EP (1998) Microsurgical anatomy of the dural collar (carotid collar) and rings around the clinoid segment of the internal carotid artery. Neurosurg 42: 869-886

16. Taptas JN (1949) La loge du sinus caverneux sa constitution et les rapports des éléments vasculaires et nerveux qui la traversent. Sem Hop 40: 1719-1722

17. Tsutsumi S, Rhoton AL (2006) Microsurgical anatomy of the central retinal artery. Neurosurg 59: 870-879

18. Umansky F, Nathan H (1982) The lateral wall of the cavernous sinus. With special reference to the nerves related to it. J Neurosurg 56: 228-234

19. Weninger WJ, Streicher J, Muller GB (1997) Anatomical compartments of the parasellar region: adipose tissue bodies represent intracranial continuations of extracranial spaces. J Anat 191: 269-275

20. Winslow (1732) Exposition anatomique de la structure du corps humain. Vol 31. London

21. Yang Y, Wang H, Shao Y, Wei Z, Zhu S, Wang J (2006) Extradural anterior clinoidectomy as an alternative approach for optic nerve decompression: Anatomic study and clinical experience. Neurosurg 59: 253-262

.

Les applications pathologiques du concep inter-périostéo-dural

Remarques d'ordre général

Cette conception de la dure-mère s'illustre d'exemples cliniques multiples empruntés à la neurochirurgie. L'hématome sous-dural, pathologie fréquente du sujet agé survenant dans un contexte de traumatismes crâniens, favorisé par un traitement anticoagulant, n'existe pas stricto sensu puisqu'il n'y a pas d'espace sous dural. Cet hématome se constitue dans l'épaisseur du feuillet encéphalique et respecte en général les espaces sous-arachnoidiens, le différenciant de l'hémorragie sous-arachnoidienne. C'est l'existence de cet espace virtuel inter-dural qui explique son aspect festonné, cloisonné, en général adhérent aux sutures. De même l'aspect de coque externe correspond à cette structure collagénique du feuillet encéphalique comme cela a été démontré lorsqu'on étudie en microscopie électronique la coque de ces hématomes.

Méningiomes

Les méningiomes se développent à partir des cellules arachnoïdiennes expliquant le fait qu'ils peuvent apparaître à des endroits où il n'y a pas de dure-mère (terme impropre de méningiome sans attache durale) comme les toiles choroïdiennes ou les fissures choroïdiennes. Lorsqu'ils se développent, très rapidemment ils vont coloniser le feuillet encéphalique puisque celui-ci est « connecté » aux cellules archnoïdiennes, et utiliser la matrice collagénique de ce feuillet pour ce développer. C'est cette constatation qui est à l'origine des descriptions radiologiques historiques des méningiomes avec la notion d'angle de raccordement, de prise de contraste en queue de comète. À ce titre, la classification de Simpson est ambiguë puisqu'elle permet d'apprécier la qualité de l'exérèse d'un méningiome à partir de la résection de la dure-mère d'insertion et même si cela obéit à une vérité chirurgicale indiscutable, cela prête à confusion quant au développement de ces tumeurs.
Les méningiomes des loges caverneuses se développent à partir des cellules arachnoidiennes emportées avec les gaines durales des nerfs crâniens lorsqu'ils traversent l'espace latéro sellaire interpériostéo dural.[16] Ils se développent soit vers la fosse cérébrale moyenne,soit dans la loge inter periostéo-durale. Ces espaces communiquent largement entre eux par les sinus coronaires, véritables anastomoses inter-caverneuses. De fait, les méningiomes intra-caverneux peuvent se développer vers la loge caverneuse controlatérale, réalisant un tableau de méningiomes en U (figure ci-dessous).

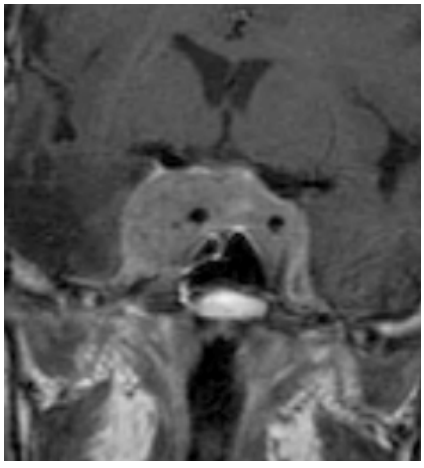

Adénomes hypophysaires

La paroi médiale de la loge caverneuse reste un sujet de controverse car elle représente la limite latérale de la loge hypophysaire. Pour certains, elle est seulement formée par la capsule hypophysaire[10] et non par de la dure-mère alors que pour la majorité des auteurs[5,8,38], elle est constituée de dure-mère. En microscopie électronique, on individualise autour de l'hypophyse ces deux structures : une structure adhérente à l'hypophyse correspondant à la capsule hypophysaire, et une structure plus épaisse en continuité avec la dure mère de l'étage antérieur ayant le même aspect à fort grossissement (x2000). L'invasion des loges caverneuses par un adénome hypophysaire est important à établir car il représente souvent la limite du traitement chirurgical. Kawase et al.[16] a étudié les « points faibles » des loges caverneuses et a montré que ce sac dural hypophysaire était par endroits très fin, inexistant parfois, Yokoyama et al.,[39] expliquant le fait que certains microadénomes hypophysaires puissent être invasifs alors qu'ils n'ont aucun signe d'agressivité histologique. Par ailleurs les adénomes invasifs peuvent se développer vers l'orbite en « utilisant » le concept inter-périostéo-dural et en s'immiscant entres les gaines durales des nerfs au niveau de la fissure orbitaire supérieure pour se développer vers l'orbite (figure ci-dessous). Si l'extension tumorale se fait par la gaine durale du nerf optique, elle reste limitée à la gaine et l'extension ne se fait pas dans l'espace inter-périostéo-dural mais dans la continuité des espaces sous arachnoidiens autour du nerf optique.



Exemple de prolactinome invasif “utilisant” la fissure orbitaire supérieure pour se dévelloper dans l’orbite

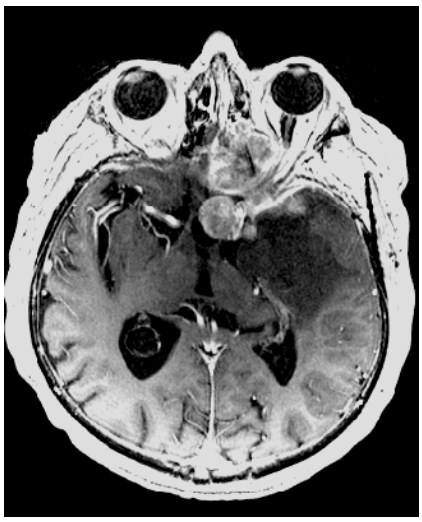

Autre exemple d’adénome envahissant l’orbite par invasion de la paroi médiale de l’orbite à partir du sinus sphénoïdal: il ne se développe pas stricto sensu dans l’orbite mais l’envahit “de dehors en dedans”

Angiolipomes

Les angiolipomes sont des tumeurs rares, constituées de tissus graisseux et de vaisseaux anormaux.[1,2] Ils sont décrits essentiellement au niveau de l'espace épidural rachidien, de la loge caverneuse et de l'orbite.[2,11,18,28,35,37] Nous avons eu l'opportunité d'opérer une patiente d'un angiolipome du sinus caverneux. A partir d'une revue des données de la littérature et de nos travaux originaux, nous avons proposé que l'angiolipome soit la tumeur emblématique du concept inter périostéo dural et deviennent l'illustration pathologique du concept inter périostéo-dural. Ce travail a fait l'objet d'une publication soumise à la revue **Journal of Neurosurgery**.

LATERAL SELLAR ANGIOLIPOMA : THE EMBLEMATIC TUMOR OF THE EXTRA-DURAL NEURAL AXIS COMPARTMENT

Patrick François[(1)], Ilyess Zemmoura[(1)], Anne Marie Bergemer Fouquet[(2)], Michel Jan[(1)], Stéphane Velut [(1,3)]

1 : CHRU deTours, Service de Neurochirurgie, Tours, France
2 : CHRU deTours, Service d'anatomie et cytologie pathologiques, Tours, France.
3 : Université François Rabelais de Tours, Laboratoire d'anatomie, Tours, France

KEY WORDS : Anatomy, angiolipoma, cavernous sinus, fat, skull base surgery

Address reprint requests to:

Patrick FRANÇOIS, M.D.

Department of Neurosurgery
François Rabelais University
10 Boulevard Tonnellé
F-37044 Tours, France
Email : francois@med.univ-tours.fr
Phone: 00 (33) 02 47 47 37 16
Fax: 00 (33) 02 47 47 80 96

Abstract

Object:

Angiolipomas are rare tumors of the central nervous system which most frequently develop in the orbit, the cavernous space and the epidural space of the spine. We report the case of a patient who presented an angiolipoma of the cavernous space. Using data from the published literature and an experimental anatomic approach, we demonstrate that the cavernous space contains adipose tissue. Consequently, we suggest that angiolipomas constitute an emblematic tumor of the interperiostal dural concept.

Method:

We report the clinical, radiological and histological data of a patient who presented a tumor of the cavernous space. We prepared two encephalic extremities (four cavernous spaces) using a special anatomical preparation consisting in the injection of colored neoprene latex followed by six-months immersion in a formaldehyde solution enriched with hydrogen peroxide in order to soften the bony structures (coronal sections) while leaving the fat in the cavernous space intact.

Results:

This case report corroborates previously published clinical data and showed that the tumor was a hamartoma constituted by mature fat cells associated with vascular proliferation. The tumor developed in the cavernous space which is an interperiostal dural space extending from the sphenoid periosteum (osteoperiostal layer) to the superior and lateral walls of the cavernous space (encephalic layer). This space represents an anatomical continuum extending from the coccyx to the orbit: the interperiostal-dural concept. It contains fat tissue which is abundant at the level of the orbit and the epidural spinal space and sparser at the level of the cavernous spaces, as was shown in our anatomical study.

Conclusion:

We suggest that angiolipomas represent the emblematic tumor of the interperiostal dural concept since they essentially develop in these spaces which contain fat tissue.

Introduction:

Angiolipomas of the central nervous system are rare benign tumors originating in mesenchymal tissue which are constituted by a proliferation of mature fat cells and endothelial cells.[1,17,23,33] They most frequently develop in the epidural space of the spine, the cavernous spaces and more rarely in the orbit.[2,5,8,10,12,13,15,16,18,22,24,26,28,31,35,36,37] Rare publications have reported them outside of these locations, particularly at the level of the tectal lamina and the thalamus.[21,25] Angiolipomas represent an anatomopathological entity distinct from lipomas and their anatomopathological substratum and localizations are different (they mainly develop along the midline: the corpus callosum, the quadrigeminal plate, and the interhemispheric fissure.[6,32,38] This new case of angiolipoma of the lateral sellar compartment (LSC) and an extensive review of the literature prompted us to use a novel anatomical technique and apply it to the LSC and its contents. This technique allowed us to soften the bony structures without altering its fat tissue and thus determine whether fat tissue was present in the LSC.

The operative findings in this case combined with the anatomical technique we used and a critical review of the published literature leads us to suggest that angiolipomas are a pathological illustration of the interperiostal dural concept.

Material and Method:

Clinical and radiological data:

We report the case of a 56-year old woman with no significant past medical history who presented with intracranial hypertension which had been present for two months. Neurological examination revealed an incomplete extrinsic left third cranial nerve palsy with ptosis and diplopia. Facial sensitivity was normal and visual acuity was 6/10° on the right and 10/10° on the left.

Magnetic resonance imaging (MRI) showed a well-defined tumor measuring 35x40x35 cm in the left cavernous space with extension to the middle cerebral fossa and hypophyseal space. The tumor was hyperintense on T2 flair-weighted MR sequences and enhance strongly after gadolinium administration (Fig. 1 AB). T1-weighted fat sat MR sequences showed a clear-cut hyposignal in comparison to the adjacent cerebral tissue thereby confirming that the tumor consisted in fat tissue (Fig. 1C).

Anatomical dissections:

We dissected 2 encephalic extremities (4 LSC) after injecting them with neoprene latex, colored red for the arteries following catheterization of the common carotid and vertebral arteries of the neck and colored blue for the veins following catheterization of the internal jugular veins. They were then fixed by immersion for six months in a 10 % formaldehyde solution containing 5 % hydrogen peroxide with regular renewal of the immersion baths. Using this technique, we were able to soften the bony structures without affecting the fat tissue. After the six-month immersion treatment, we extracted the brains and performed coronal sections of the cavernous spaces using an operating microscope (Zeiss OPMI 9FC). We took photographs with a Hasselblad camera (Hasselblad AB, Göteborg, Sweden) and developed them using Kodak film (Ektachrome 160T). We obtained the latex (#671) from E.I. Du Pont de Nemours-Dow Elastomers.

Results:

Operative data:

We removed the tumor by using a left pterional approach after prepared a cervical approach, allowing good exposure of the internal carotid artery in the neck.

As soon as the Sylvian fissure was opened, the tumor became clearly visible. It was covered by dura mater, had developed inside the cavernous space and bulged towards the middle cerebral fossa. We opened the lateral wall of the cavernous space and removed the tumor. The oculomotor and ophthalmic nerves ran along the lateral surface of the tumor thus confirming that the tumor's epicenter was indeed in the cavernous space. Macroscopically, the tumor was unusual: it was raspberry-colored in some areas and yellowish in others. In addition, it readily bled with the slightest contact, indicating that it was richly vascularized. As a result, adequate hemostasis was difficult to obtain. We performed partial removal (80 %) with piecemeal resection and aspiration after identifying the different vascular and nervous structures in the cavernous space. We used Surgicel ® and dabbing with surgical cotton to obtain hemostasis. The patient presented a post-operative complication consisting in transient weakness of cranial nerves III and V1 which partially regressed over a 12-month period. Follow-up MRI showed the persistence of some residual, non-growing tumor tissue in the cavernous space.

Neuro-pathological data:

The tumor was composed of mature fat cells and abnormal, thin-walled blood vessels which produced a pseudo-angioma appearance in some places (Fig. 1D). Histologically, the tumor was compatible with an angiolipoma of the cavernous space.

Anatomical data:

The results in the two anatomical preparations (4 cavernous spaces) were identical: the cavernous space consisted in an interperiostal dural space comprised between the encephalic layer of the dura mater and the osteoperiostal layer. The encephalic layer formed the lateral wall, the roof and the supero-medial wall of the cavernous space and was contiguous with the encephalic layer of the anterior and middle floor of the skull base. The osteoperiostal layer adhered to the bone and formed the infero-medial wall of the cavernous space. The cavernous space was filled with islets of fat tissue located lateral to the intracavernous carotid artery and medial to the lateral wall of the cavernous space (Fig. 2). The fat islets lied between the neurovascular elements which went through the cavernous space and were more developed at the level of the antero-superior compartment of the cavernous space. The cavernous space also contained venous lakes which had colored blue during our anatomical preparation.

Discussion

Angiolipomas are rare tumors of the neural axis which are different from lipomas. They most frequently appear in the thoracic spine where they are called “extra dural” angiolipomas since they develop between the encephalic layer of the dura mater which forms the dural sheath of the spinal cord and the osteoperiostal layer which covers the vertebrae.[1,2,10,24,33,36] This interperiostal dural space is improperly called the epidural space. It contains an important quantity of fat tissue which facilitates the movements of the dural sheath of the spine (spinal prolongation of the encephalic layer) in the spinal canal which is covered by the osteoperiostal layer. Angiolipomas develop from this fat tissue. They have also been reported to develop in the cavernous space and the orbit.[5,12,16,22,26,28,35] The epidural spinal space, the cavernous space and the orbit are areas where the interperiostal dural space is larger and filled with fat tissue and venous lakes. The interperiostal dural concept in the cavernous space was first described by Taptas.[29,30] He individualized the encephalic and osteoperiostal layers of the dura mater after closely examining the walls of the cavernous space. Thus, its lateral wall is formed by the apposition of two encephalic layers: an external layer which is continuous with the middle cerebral fossa layer and an internal layer formed by the apposition of the dural sheathes of the oculomotor , ophthalmic and trochlear nerves as can be seen in our histological sections. The medial wall is formed cephalad by the hypophyseal dural bag, a meningeal bag suspended from the sellar diaphragm which was described by Destrieux, et al.[4] Caudally, the medial wall is formed by the osteoperiostal layer which covers the body of the sphenoid. The roof of the cavernous space is formed by the encephalic layer with covers the anterior clinoid process. It is perforated by the oculomotor and trochlear nerves which carry the encephalic layer with them and which makes up their dural sheathes. These entry points in the dura constitute areas of least resistance for the extension of tumors in the cavernous space towards the subarachnoid spaces.[11,14] Indeed, some angiolipomas which have been described in the suprasellar region are in fact tumors of the cavernous space which have extended to the suprasellar region by passing through these porus.[16,26] The meningeal architecture of the cavernous space is shown in figure 2 and illustrates that the two layers are isolated. The cavernous space contains venous spaces which communicate with the orbital veins, the superior petrosal sinus and the petroclival

venous confluent.[3] As we have shown in our anatomical dissections (figure 2), the cavernous space contains abundant fat tissue. Weninger, et al.[34] have demonstrated that the parasellar region in the foetus and in infants consistently contains these fatty islets; they have been described in the orbital compartment, the cavernous space and the pterygo-maxillary fossa. Consequently, this fat tissue is present as early as in the foetal stage and is not secondary to degeneration related to aging. These anatomical data have been confirmed by data obtained with medical imagery which have frequently demonstrated the presence of fat tissue in the cavernous space.[9,27] Parkinson[19,20] has extended this conception of the dura mater of the cavernous space to include an anatomical concept: the interperiostal dural concept which constitutes a veritable anatomical continuum extending from the orbit to the coccyx. This concept is illustrated in figure 3 and summarizes the distribution of the encephalic and osteoperiostal layers. In the orbit, the encephalic layer is constituted by the dural sheath of the optic nerve which is an invagination of the encephalic layer of the anterior floor at the level of the falciform ligament. The osteoperiostal layer is represented by the periorbit and is adherent to the orbit. Caudally, at the *foramen magnum*, the osteoperiostal layer is represented by the vertebral periosteum while the encephalic layer forms the dural sheath. At this point, the interperiostal dural space is wide, just like it is at the level of the orbit and the cavernous space: this corresponds to the epidural spinal space. When the two layers are separated one from the other, this space contains fat tissue and venous lakes, a primary condition for the interperiostal dural concept.[19,20] Recently, we demonstrated that this concept is valid by using electron-microscopy to examine these layers.[7] Indeed, the encephalic layer we “observed” is formed by a linkage of collagen fibers covered by an amorphous substance. In fact, the encephalic layer is constituted by a deep cellular layer (dural border cell) and a superficial layer. An amorphous, less resistant substance extends between them. Under these conditions, the removal of the encephalic layer exposes the amorphous substance and in fact, only the superficial layer of the encephalic layer is actually removed. The deeper, cellular layer remains adherent to the arachnoid. This aspect is not observed at the level of the osteoperiostal layer. These morphological findings corroborate the anatomic data pertaining to the distribution of the layers of the dura mater. Thus, angiolipomas electively develop between the two layers of the dura mater, in the interperiostal dural space, and originate in the fat tissue which is present.

Angiolipomas are composite tumors constituted by mature fat tissue associated with vascular proliferation. These findings help to explain the tumor's appearance when viewed by MRI. The observed hypersignal during T1-weighted MR sequences strongly suggests the diagnosis and enhancement after Gadolinium injection confirms the hypervascular nature of these tumors. T1-weighted MR sequences, with suppression of fat tissue, indicate that the tumors were derived from fat tissue. These data are identical to data published in the literature on spinal angiolipomas.[36] In our case the extension to the hypophyseal space, which was initially described, was incorrect. Angiolipomas develop between the osteoperiostal and encephalic layers which form the hypophyseal dural bag. In fact, they are located in the coronary sinuses, which constitute a veritable intercavernous anastomosis. Considering all of these epidemiological, histological, radiological and anatomical findings, we suggest that angiolipomas are emblematic tumors of the interperiostal dural concept.

Table 1 : *Diagnostic presentation of patients with sellar and parasellar angiolipomas*

Year	Author	Sex	Age	Symptoms	Operative findings	Outcome
1981	Takeuchi [28]	F	72	Acute subarachnoid hemorrhage	Profuse bleeding, partial removal	death
1987	Wilkins [35]	F	75	Seizures, headache, 3rd nerve palsy	Profuse bleeding, partial removal	Improved
1994	Lach [16]	F	65	Diplopia, 3rd nerve palsy	Profuse bleeding, partial removal	Improved
1995	Shuangshoti [27]	M	8	Retro orbital pain	Well encapsulated, total removal	Improved
1998	Pirotte [22]	F	70	3rd nerve palsy, temporal hemianopsia	Profuse bleeding, partial removal (75%)	Improved
2008	Kolenc [12]	F	51	Headache, lower back pain	Profuse bleeding, partial removal	Improved
		M	62	Diplopia, headache, progressive visual loss due to thrombosis of the basilar artery	Profuse bleeding, partial removal	Improved
2009	This report	F	56	Diplopia, headache, 3rd nerve palsy	Profuse bleeding, partial removal	Improved

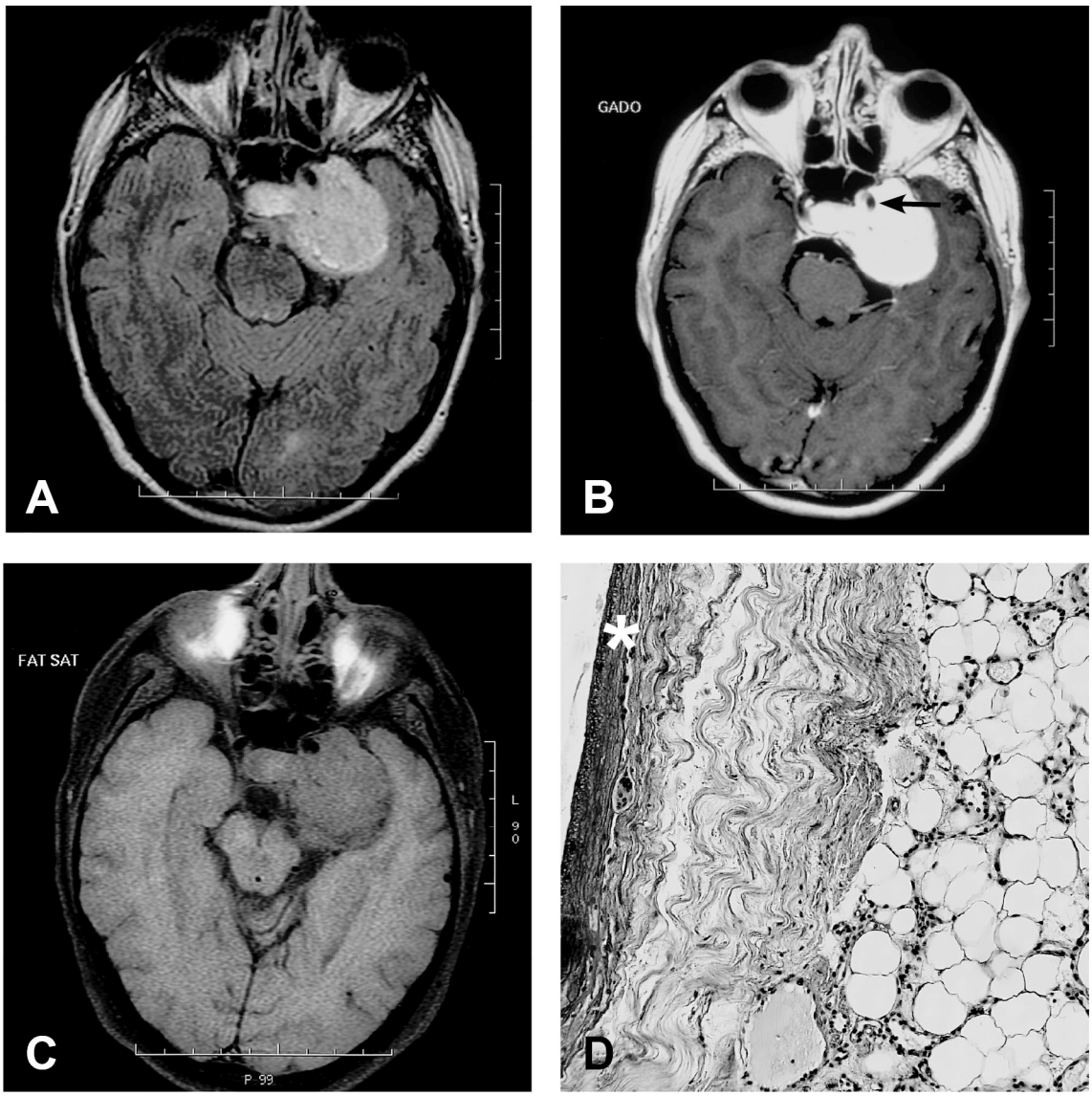

Figure 1 :

A : Axial T2 flair MR sequence of a left angiolipoma located in the Lateral Sellar Compartment with intrasellar extension. **B** : Axial T1-weighted MR sequence after gadolinium injection: the tumor became homogeneously hyperintense. The anterior bend of the carotid artery is totally encased in the lateral sellar compartment (arrows). **C** : On the fat saturation MR sequence, the angiolipoma is iso-intense to gray matter which is typical of tumors with a fat component. **D** : Paraffin section showing typical angiolipoma patterns with mature adipose cells interspersed with thin-walled vascular channels (hematoxylin and eosin. Obj x10). The tumor is covered by the encephalic layer of the lateral wall of the cavernous sinus (*).

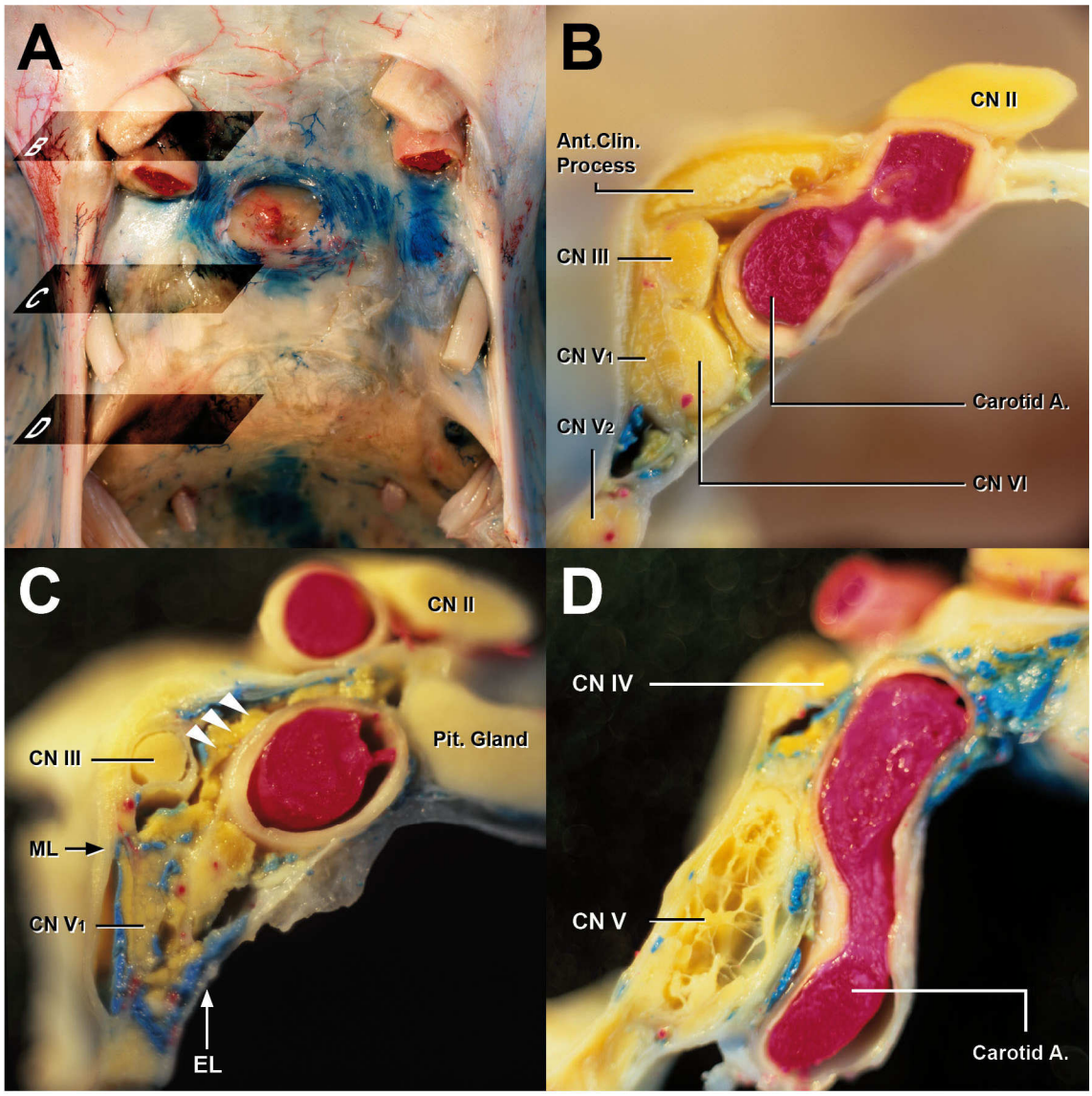

Figure 2 :

A : Superior view of the sellar region with coronal sections (B, C, D) passing through the left Lateral Sellar Compartment (LSC). The LSC is an interperiosteodural space limited laterally by a meningeal layer. The medial wall is composed of two parts: the sphenoidal part which corresponds to the endosteal layer and the hypophyseal part which corresponds to the encephalic (meningeal) layer. **B** : Anterior coronal section passing through the anterior bend of the carotid artery. **C** : Middle coronal section of the cavernous sinus. The adipose tissue (yellow-colour, indicated by arrows) occupies a large island filling most of the space between the arteries, nerves, veins and dura layers. **D** : posterior coronal section passing through the posterior bend of the carotid artery. A, Artery; Ant, Anterior; Clin, Clinoid; CN, Cranial Nerve; EL, Endosteal Layer; ML, Meningeal layer; Pit, Pituitary.

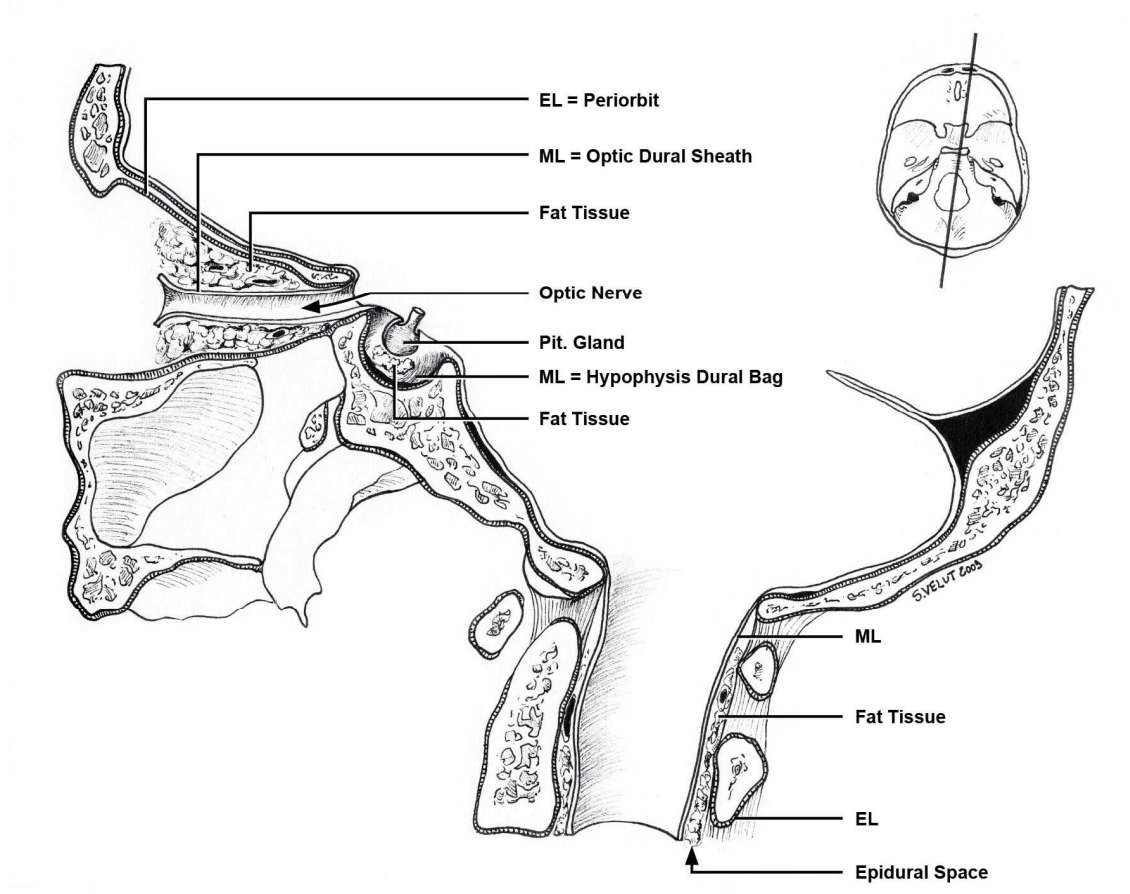

Figure 3 :

Diagram representing a paramedian section of the nevral axis showing the distribution of the encephalic and osteoperiostal layers of the dura mater. These two layers are separated from one another at the level of the orbit, the cavernous space and the epidural spinal space and delimit the interperiostodural space, a veritable anatomical continuum extending from the coccyx to the orbit. The two layers are separated from one another by fat tissue and venous lakes. EL, Endosteal Layer; ML, Meningeal layer; Pit, Pituitary.

Références :

1. Andaluz N, Balko G, Bui H, Zuccarello M. Angiolipomas of the central nervous system. **J Neurooncol 49:**219-230, 2000

2. Bardosi A, Schaake T, Friede RL, Roessmann U. Extradural spinal angiolipoma with secretory activity. An ultrastructural, clinico-pathological study. **Virchows Arch A Pathol Anat Histopathol 406:**253-259, 1985

3. Destrieux C, Velut S, Kakou MK, et al: A new concept in Dorello's canal microanatomy: the petroclival venous confluence. **J Neurosurg 87:**67-72, 1997

4. Destrieux C, Kakou MK, Velut S, et al: Microanatomy of the hypophyseal fossa boundaries. **J Neurosurg 88:**743-752, 1998

5. Feinfield RE, Hesse RJ, Scharfenberg JC: Orbital angiolipoma. **Arch Ophtalmol 106:**1093-1095, 1988

6. François P: Lipome du corps calleux. **Neurochirurgie 44 (Suppl. 1):**125-126, 1998

7. François P, Travers N, Lescanne E, et al: The interperiosteodural concept applied to the perisellar compartment: a microanatomical and electron microscopic study. **J Neurosurg** (in press)

8. Guzey FK, Bas NS, Ozkan N, et al: Lumbar extradural infiltrating angiolipoma: a case report and review of 17 previously reported cases with infiltrating spinal angiolipoma. **Spine J 7:**739-744, 2007

9. Hosoya T, Kera M, Suzuki T, et al: Fat in the normal cavernous sinus: **Neuroradiology 28:**264-266,1986

10. Hungs M, Paré LS: Spinal angiolipoma: case report and literature review. **J Spinal Cord Med 31:**315-318,2008

11. Kawase T, van Loveren H, Keller JT, et al: Meningeal architecture of the cavernous sinus: clinical and surgical implications. **Neurosurgery 39:**527-536, 1996

12. Kolenc D, Zarković K, Jednacak H, Ozretić D, Habek M. Sellar angiolipomas: two case reports and a review of the literature. **J Neurooncol 89:**109-112, 2008

13. Konya D, Ozgen S, Kurtkaya O, Pamir NM. Lumbar spinal angiolipoma: case report and review of the literature. **Eur Spine J 15:**1025-1028, 2006

14. Krivosic I: Histoarchitecture of the cavernous sinus, in Dolenc VV (ed): **The cavernous sinus. A Multidisciplinary Approach to Vascular and Tumorous lesions.** Vienna: Springer-Verlag, 1987, pp 117-129

15. Kujas M, Lopes M, Lalam TF, Fohanno D, Poirier J. Infiltrating extradural spinal angiolipoma. **Clin Neuropathol 18:**93-98, 1999

16. Lach B, Lesiuk H: Intracranial suprasellar angiolipoma: Ultrastructural and immunohistochemical features. **Neurosurgery 34:**163-167, 1994

17. Lin JJ, Lin F: Two entities in angiolipoma. A study of 459 cases of lipoma with review of literature on infiltrating angiolipoma. **Cancer 34**:720-727, 1974

18. Nanassis K, Tsitsopoulos P, Marinopoulos D, et al: Lumbar spinal epidural angiolipoma. **J Clin Neurosci 15:**460-463, 2008

19. Parkinson D: Extradural neural axis compartment. **J Neurosurg 92:**585-588, 2000a

20. Parkinson D: History of the extradural neural axis compartment. **Surg Neurol 54:**422-431, 2000b

21. Pawar SJ, Sharma RR, Karapurka AP, et al: Angiolipoma of the right inferior colliculus: a rare central cause of hearing loss and limb ataxia. **J Clin Neurosci 10:**346-348, 2003

22. Pirotte B, Krischek B, Levivier M, et al: Diagnostic and microsurgical presentation of intracranial angiolipomas. **J Neurosurg 88:**129-132, 1998

23. Russell DS, Rubinstein LJ. **Pathology of tumors of the nervous system.** Williams & Wilkins, 1989, ed 5, p 708

24. Samdani AF, Garonzik IM, Jallo G, Eberhart CG, Zahos P. Spinal angiolipoma: case report and review of the literature. **Acta Neurochir (Wien) 146:**299-302, 2004

25. Shuangshotti S, Vajragupta L: Angiolipoma of thalamus presenting with abrupt onset suggestive of cerebrovasular disease. **Clin Neuropathol 14:**82-85, 1995

26. Shuangshoti S, Wangsuphachart S. Angiolipoma of suprasellar region. **J Med Assoc Thai 78:**631-634, 1995

27. Stricof DD, Gabrielsen TO, Latack JT, et al: CT demonstration of cavernous fat. **American Journal of Neuroradiology 10:**1199-1201, 1989

28. Takeuchi J, Handa H, Keyaki A, Haibara H, Ozaki S. Intracranial angiolipoma. **Surg Neurol 15:**110-113, 1981

29. Taptas JN: La loge du sinus caverneux sa constitution et les rapports des éléments vasculaires et nerveux qui la traversent. **Sem Hop 40:**1719-1722, 1949

30. Taptas JN: the so-called cavernous sinus: a review of the controversy and its implications for neurosurgeons. **Neurosurgery 11:**712-717, 1985

31. Turgut M. Spinal extradural angiolipoma, with a literature review. **Childs Nerv Syst 20:**73-74, 2004

32. Uchino A, Hasuo K, Matsumoto S, et al.MRI of dorsal mesencephalic lipomas. **Clin Imaging 17:**12-16, 1993

33. Weill A, Melançon D, Del Carpio R, Tampieri D, Ethier R. Angiolipoma of the central nervous system. **Rev Neurol (Paris)147:**285-292, 1991

34. Weninger WJ, Streicher J, Muller GB: Anatomical compartments of the parasellar region: adipose tissue bodies represent intracranial continuations of extracranial spaces. **J Anat 191:**269-275, 1997

35. Wilkins PR, Hoddinott C, Hourihan MD, et al: Intracranial angiolipoma. **Journal of Neurol, Neurosurg, and Psychatry 50:**1057-1059, 1987

36. Yamashita K, Fuji T, Nakai T, et al: extradural spinal angiolipoma: report of a case studied with MRI. **Surg Neurol 39:**49-52, 1993

37. Yen HL, Tsai SC, Liu SM. Infiltrating spinal angiolipoma. **J Clin Neurosci 15:**1170-1173, 2008

38. Yildiz H, Hakyemez B, Koroglu M, et al. Intracranial lipomas: importance of localization. **Neuroradiol 48:**1-7, 2006

Acknowledgments

We are indebted to Donald SCHWARTZ, M.D., from Tours for his help in proofreading this paper. We also thank Gerald DELUERMOZ, Jean Paul DA SILVA (Laboratoire d'Anatomie, Faculté de Médecine de Tours), Daniel BOURRY (Service iconographie, Faculté de Médecine) for their technical help.

The neoprene latex (#671) was a gift from Laboratoires Safic-Alcan, Puteaux, France

This study was financially supported by « Association du Don du Corps », Laboratoire d'Anatomie, Faculté de Médecine, Tours, France.

Perspective de travail

L'hypotension intra-crânienne est une pathologie d'individualisation récente se révélant par des céphalées positionnelles, calmées par le décubitus dorsal. Le substratum anatomique est une brèche durale spontanée intéressant généralement le rachis thoracique, à l'origine de fuites de liquide cérébrospinal. Le diagnostic est suspecté à partir des caractéristiques cliniques, de l'existence d'un hématome sous-dural bilatéral en l'absence de traumatisme crânien ou de traitement anticoagulant. Le diagnostic est confirmé par la mise en évidence de la brèche durale. L'imagerie par IRM permet d'affirmer le diagnostic en montrant l'existence d'une pachyméningite importante (figure ci-dessous). Cette pachyméningite est particulièrement visible à la convexité sur les coupes coronales en pondération T1 après injection de gadolinium. La physiopathologie de cette pachyméningite est très intéressante et est à l'origine de notre hypothèse de travail suivante. La fuite de liquide cérébrospinal est à l'origine d'une ptose cérébrale (pont plaqué sur le clivus, amygdales cérébelleuses engagées) et l'interface entre les feuillets de la dure-mère est soumise à des tractions tendant à ouvrir cette zone de moindre résistance. Cette constatation expliquerait l'apparition d'un hématome sous-dural mais aussi la prise de contraste des méninges témoignant d'une mise en tension de cet espace. Pour documenter ce fait, nous programmons de réaliser des prélévements monoblocs de l'os, les méninges et l'encéphale sur des cadavres frais après avoir soit vidangé les espaces sous-arachnoidiens par ponction lombaire soustractive ou à l'inverse provoqué une expansion de ces espaces après adjonction de liquide dans les

espaces sous-arachnoïdiens. L'étude de cette interface en microscopie électronique est intéressante et ce d'autant plus que le volume de l'espace sous-arachnoidien peut être modifié. Ce travail nécessite de pouvoir disposer de cadavres frais (décès de moins de 24 heures) de façon à minimiser les modifications du cerveau sous-jacent, de mettre au point une technique de prélévement monobloc sans induire d'artifice de prélévement.

Conclusion

Ce travail anatomique a documenté une conception ancienne de la dure mère, largement utilisée par la communauté neurochirurgicale mais non démontrée à un niveau microscopique. Les feuillets de la dure-mère ont un aspect différent, en microscopie à balayage, sur leurs surfaces expliquées par nos connaissances actuelles concernant l'histologie des méninges. Le concept inter périostéo dural appliqué à la région périsellaire a de multiples applications neurochirurgicales. Nous proposons que l'angiolipome soit l'illustration pathologique de ce concept et devienne la tumeur emblématique du concept inter périostéo-dural. Par ailleurs, cette anatomie de la dure-mère peut s'appliquer aux méninges de la convexité et expliquer la physiopathologie encore obscure de l'hypotension intra cranienne.

Références bibliographiques

1. Andaluz N, Balko G, Bui H, Zuccarello M. Angiolipomas of the central nervous system. *J Neurooncol* 2000; 49**:**219-230.

2. Bardosi A, Schaake T, Friede RL, Roessmann U. Extradural spinal angiolipoma with secretory activity. An ultrastructural, clinico-pathological study. *Virchows Arch A Pathol Anat Histopathol* 1985; 406:253-259.

3. Bichat X. *Anatomie générale*. Tome 4. 1801, Broson-Gabon, Paris.

4. Bonnet P. La loge caverneuse et les syndromes de la loge caverneuse. *Arch d'ophtalmologie* 1955; 15: 332-357.

5. Brassier G, Lasjaunias P, Guégan Y, Pecker J. Microsurgical anatomy of collateral branches of the intracavernous internal carotid artery. In: Dolenc VV, editor. *The cavernous sinus. A multidisciplinary approach to vascular and tumorous lesions*. Wien ; New York: Springer-Verlag, 1987: 419.

6. Chi JG, Lee MH: Anatomical observations of the development of the pituitary capsule. *J.Neurosurg* 1980; 52:667-670.

7. Ciric I: On the origin and nature of the pituitary gland capsule. *J Neurosurg* 1977; 46:596-600.

8. Destrieux C, Kakou MK, Velut S, Lefrancq T, Jan M. Microanatomy of the hypophyseal fossa boundaries. *J Neurosurg* 1998; 88: 743-52.

9. Destrieux C, Velut S, Kakou MK, Lefrancq T, Arbeille B, Santini JJ. A new concept in Dorello's canal microanatomy: the petroclival venous confluence. *J Neurosurg* 1997; 87: 67-72.

10. Dietemann JL, Kehrli P, Maillot C, Diniz R, Reis M, Jr., Neugroschl C, et al. Is there a dural wall between the cavernous sinus and the pituitary fossa? Anatomical and MRI findings. *Neuroradiology* 1998; 40: 627-30.

11. Feinfield RE, Hesse RJ, Scharfenberg JC. Orbital angiolipoma. *Arch Ophthalmol* 1988; 106: 1093-1095.

12. Frederickson RG. The subdural space interpreted as a cellular layer of meninges. *Anat Rec* 1991; 230: 38-51.

13. Friede RL, Schachenmayr W, The origin of subdural neomembranes. II. Fine structure of Neomembranes. *Am J Pathol* 1978; 92: 69-84.

14. Haines DE, Harkey HL, al-Mefty O. The "subdural" space: a new look at an outdated concept. *Neurosurgery* 1993; 32: 111-20.

15. Harris FS, Rhoton AL. Anatomy of the cavernous sinus. A microsurgical study. *J Neurosurg* 1976; 45: 169-80.

16. Kawase T, van Loveren H, Keller JT, Tew JM: Meningeal architecture of the cavernous sinus: clinical and surgical implications. *Neurosurgery* 1996; 39:527-536.

17. Kehrli P, Ali M, Reis M, Jr., Maillot C, Dietemann JL, Dujovny M, et al. Anatomy and embryology of the lateral sellar compartment (cavernous sinus) medial wall. *Neurol Res* 1998; 20: 585-92.

18. Lach B, Lesiuk H: Intracranial suprasellar angiolipoma: Ultrastructural and immunohistochemical features. *Neurosurgery* 1994; 34:163-167.

19. Lescanne E, Velut S, Lefrancq T, Destrieux C. The internal acoustic meatus and its meningeal layers: a microanatomical study. *J Neurosurg* 2002; 97:1191-1197.

20. Lescanne E, François P, Velut S. Cerebellopontine cistern: microanatomy applied to vestibular schwannomas. *Prog Neurol Surg* 2008; 21:43-53.

21. Lescanne E, François P, Bakhos D, Velut S, Robier A, Pollak A. Vestibular schwannoma: dissection of the tumor and arachnoidal duplication. *Otol Neurotol* 2008; 29:989-994.

22. McLone D. The subarachnoid space : a review. *Child's brain* 1980; 6: 113-130.

23. Parkinson D. A surgical approach to the cavernous portion of the carotid artery. Anatomical studies and case report. *J Neurosurg* 1965; 23: 474-483.

24. Parkinson D. Human spinal arachnoid septa, trabeculae, and "rogue strands". *Am J Anat* 1991; 192: 498-509.

25. Parkinson D. Extradural neural axis compartment. *J Neurosurg* 2000a; 92: 585-588.

26. Parkinson D. History of the extradural neural axis compartment. *Surg Neurol* 2000b; 54: 422-431.

27. Patouillard P, Vanneuville G. The walls of the cavernous sinus. *Neurochirurgie* 1972; 18: 551-60.

28. Pirotte B, Krischek B, Levivier M, Bolyn S, Brucher JM, Brotchi J. Diagnostic and microsurgical presentation of intracranial angiolipomas. Case report and review of the literature. *J Neurosurg* 1998; 88: 129-32.

29. Ridley. *The anatomy of the brain*. Vol 39. London, 1695.

30. Schachenmayr W, Friede RL. The origin of subdural neomembranes. I. Fine structure of the dura-arachnoid interface in man. *Am J Pathol* 1978; 92: 53-68.

31. Taptas JN. La loge du sinus caverneux sa constitution et les rapports des éléments vasculaires et nerveux qui la traversent. *Sem Hop* 1949; 40: 1719-1722

32. Tobenas-Dujardin AC, Duparc F, Laquerriere A, Muller JM, Freger P.Embryology of the walls of the lateral sellar compartment: a propos of a continuous series of 39 embryos and fetuses representing the first six months of intra-uterine life. *Surg Radiol Anat* 2003; 25:252-258.

33. Umansky F, Nathan H. The lateral wall of the cavernous sinus. With special reference to the nerves related to it. *J Neurosurg* 1982; 56: 228-34.

34. Vesalius A: *Andreae Vesalii Bruxellensis, Scholae Medicorum Pataminae Professoris: De humani corporis fabrica libri septem.* Basilae, ex officina Ioannis Oporini, 1543. http: //www.cesr.univ-tours.fr

35. Wilkins PR, Hoddinott C, Hourihan MD, Davies KG, Sebugwawo S, Weeks RD. Intracranial angiolipoma. *J Neurol Neurosurg Psychiatry* 1987; 50: 1057-9.

36. Winslow. *Exposition anatomique de la structure du corps humain.* Vol 31. London, 1732.

37. Yamashita K, Fuji T, Nakai T, Hamada H, Kotoh K. Extradural spinal angiolipoma: report of a case studied with MRI. *Surg Neurol* 1993; 39: 49-52.

38. Yasuda A, Campero A, Martins C, Rhoton AL Jr, Ribas GC: The medial wall of the cavernous sinus: microsurgical anatomy. *Neurosurgery* 2004; 55:179-189.

39. Yokoyama S, Hirano H, Moroki K, Goto M, Imamura S, Kuratsu JI: Are nonfunctioning pituitary adenomas extending into.the cavernous sinus aggressive and/or invasive? *Neurosurgery* 2001; 49:857-863.

40. Youssef S, Kim EY, Aziz KM, Hemida S, Keller JT, van Loveren HR: The subtemporal interdural approach to dumbbell-shaped trigeminal schwannomas: cadaveric prosection. *Neurosurgery* 2006; 59:270-278.